



PATIENT

Watson White

PRESENTING CLINICAL SIGNS

Prior L FL amputation Rehab noticed R knee laxity & "clicking" Exam bilateral knee pain
Radiographs: R knee effusion & OA, L knee normal
Abnormal PE/Chem/CBC/UA Results: n/a

SPECIES

Canine

ULTRASONOGRAPHIC FINDINGS

Right Stifle

Moderate effusion within the right supra- and infra- patellar recesses is seen. The synovium and joint capsule present moderate thickening. The infrapatellar fat pad is heterogeneous in echotexture. The cranial cruciate ligament presents as a broad stump of echogenic fibers at the intercondylar eminence of the tibia surrounded by a halo of anechoic effusion. The menisci are not seen.

BREED

Doberman

SEX

MN

Left Stifle

The left stifle presents within normal limits. Scant effusion is seen within the supra- and infra- patellar recesses of the left stifle joint. The cranial cruciate ligament is well delineated and continuous. The patella tendon presents within normal limits. The menisci are not seen.

AGE

5

INTERPRETATION OF THE FINDINGS & FURTHER RECOMMENDATIONS

Consider surgical intervention in order to address the presumed biomechanical instability in the right stifle and prevent further damage to the articular structures.

INTERPRETED BY

Nele Eley, DVM
Dr. med. Vet. DipECVDI

HOSPITAL NAME

Colorado Animal
Specialty &
Emergency

REFERRING VET

Dr. Gaynor

INVOICE

54034

DATE

9-6-22



PATIENT

Watson White

SPECIES

Canine

BREED

Doberman

SEX

MN

AGE

5

INTERPRETED BY

Nele Eley, DVM
Dr. med. Vet. DipECVDI

HOSPITAL NAME

Colorado Animal
Specialty &
Emergency

REFERRING VET

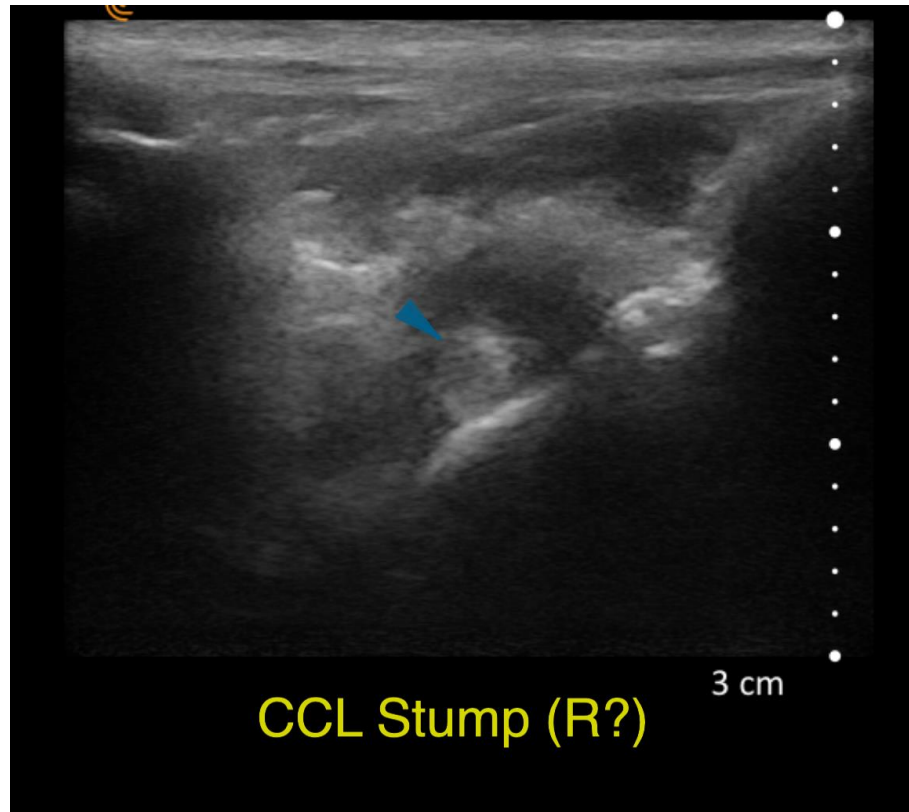
Dr. Gaynor

INVOICE

54034

DATE

9-6-22



The information and recommendations provided are based on the images presented by the referring veterinarian/sonographer. No evaluation can be communicated regarding pathology that was not visible in the image/video clips provided.

Thank you for this referral. If the clinical or image interpretation does not parallel your findings or if I can be of any further assistance please contact me.

Nele Eley, DVM, Dr. med. vet., DipECVDI
European Specialist in Veterinary Diagnostic Imaging, Cert. Radiology,
Senior lecturer University of Giessen, Germany, Veterinary Faculty, Department of Radiology
Nele.Eley@sonopath.com