



PATIENT

Henry Fleming

PRESENTING CLINICAL SIGNS

Chronic (5 year) history of intermittent RFL lameness that has progressed to a continual lameness that is easily flared by exercise. On initial examination, it was felt that the right shoulder had an increased abduction angle, especially with concurrent internal rotation, but under sedation, shoulder stability seemed normal.

SPECIES

Canine

ULTRASONOGRAPHIC FINDINGS

Right Shoulder

The right supraspinatus tendon measures 7.5mm in thickness and presents mild biceps impingement. Multiple small mineralizing foci are seen in the distal aspect of the right supraspinatus tendon. There is mild enthesopathy. The biceps presents mild to moderate generalized swelling of its synovium with mild to moderate synovial proliferations and a moderate amount of anechoic effusion. The biceps tendon itself is well delineated with no evidence of echoarchitectural changes. The musculotendinous junction is prominent. The infraspinatus bursa is moderately distended.

BREED

Pitbull X

SEX

MN

Left Shoulder

The left supraspinatus tendon measures 7.5mm in thickness and presents mild biceps impingement. Multiple small mineralizing foci are seen in the distal aspect of the left supraspinatus tendon. There is mild enthesopathy. The biceps presents mild to moderate generalized swelling of its synovium with mild to moderate synovial proliferations and a moderate amount of anechoic effusion. The biceps tendon itself is well delineated with no evidence of echoarchitectural changes. The musculotendinous junction is prominent. The infraspinatus bursa is mildly distended.

AGE

6 Years

INTERPRETED BY

Nele Eley, DVM
Dr. med. Vet. DipECVDI

ULTRASONOGRAPHIC DIAGNOSIS

- Moderate chronic bilateral supraspinatus tendinopathy with mild biceps impingement and mild to moderate biceps tenosynovitis.
- Moderate right sided and mild left sided infraspinatus bursitis.

HOSPITAL NAME

Points East West
Veterinary Services

INTERPRETATION OF THE FINDINGS & FURTHER RECOMMENDATIONS

The ultrasonographic study reveals fairly symmetric changes of the biceps tendon and rotator cuff in both shoulders. There is bilateral mineralizing supraspinatus tendinopathy with mild biceps impingement and mild to moderate secondary biceps tenosynovitis. Concurrent infraspinatus bursitis is seen as well. The changes are slightly more pronounced on the right when compared with the left side. Coexisting medial shoulder instability syndrome is a potential. The infraspinatus bursitis and synovitis is something that is seen commonly together with either chronic biceps tenosynovitis and rotator cuff injury and/or medial shoulder instability, which typically is a complex disease of the joint, its ligaments, and the surrounding tendons.

REFERRING VET

David Lane

INVOICE

54384

DATE

9-30-22



PATIENT

Henry Fleming

SPECIES

Canine

BREED

Pitbull X

SEX

MN

AGE

6 Years

INTERPRETED BY

Nele Eley, DVM
Dr. med. Vet. DipECVDI

HOSPITAL NAME

Points East West
Veterinary Services

REFERRING VET

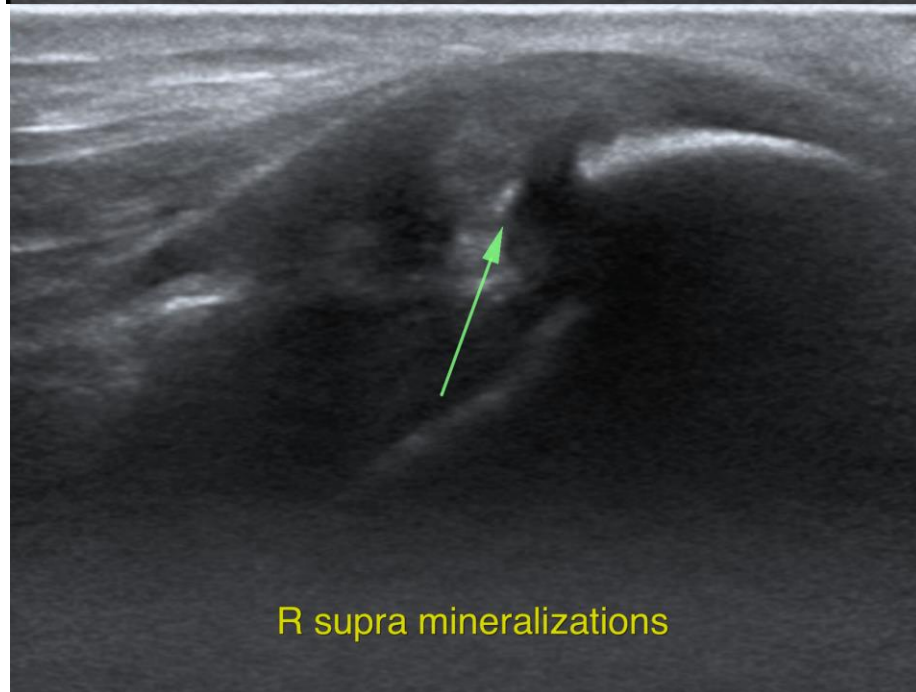
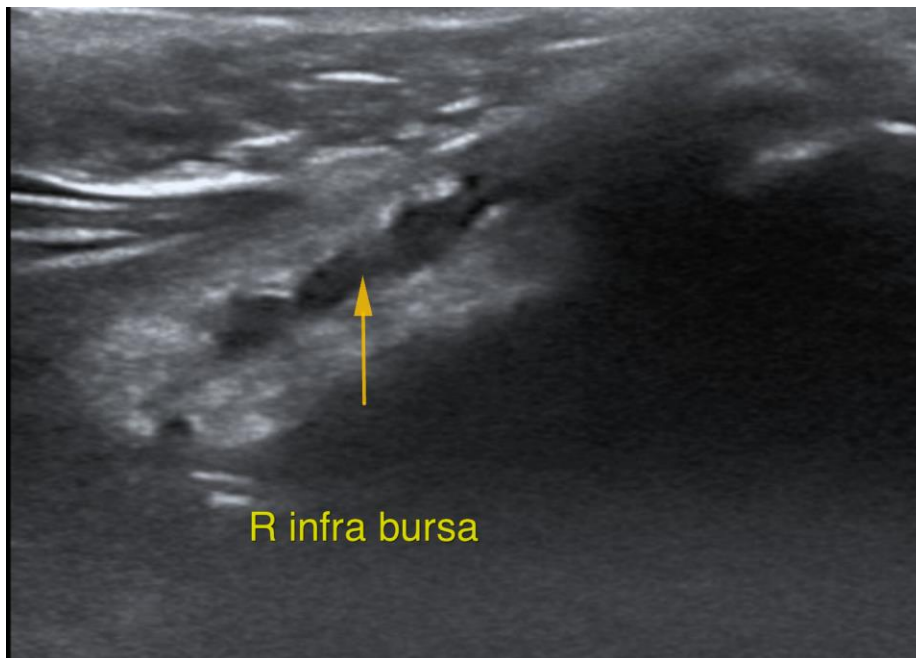
David Lane

INVOICE

54384

DATE

9-30-22





PATIENT

Henry Fleming

SPECIES

Canine

BREED

Pitbull X

SEX

MN

AGE

6 Years

INTERPRETED BY

Nele Eley, DVM
Dr. med. Vet. DipECVDI

HOSPITAL NAME

Points East West
Veterinary Services

REFERRING VET

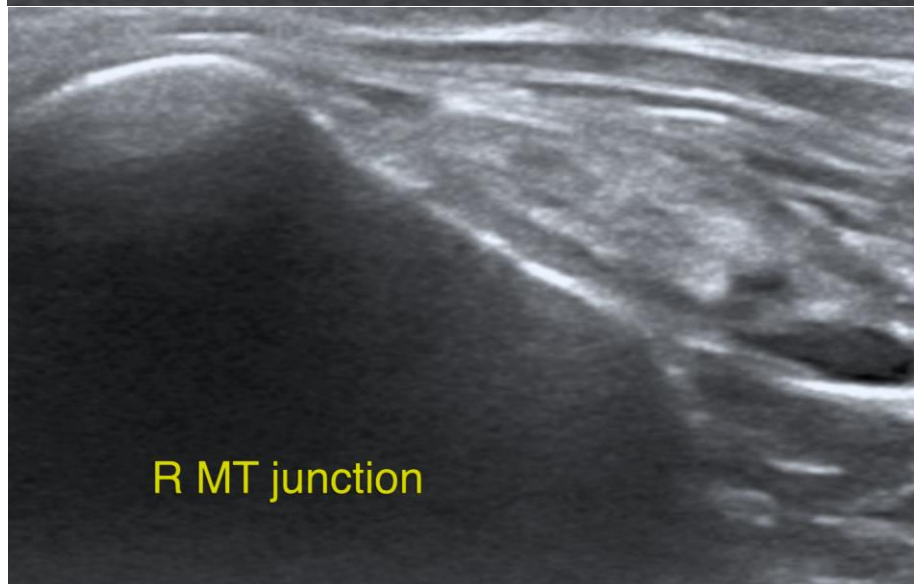
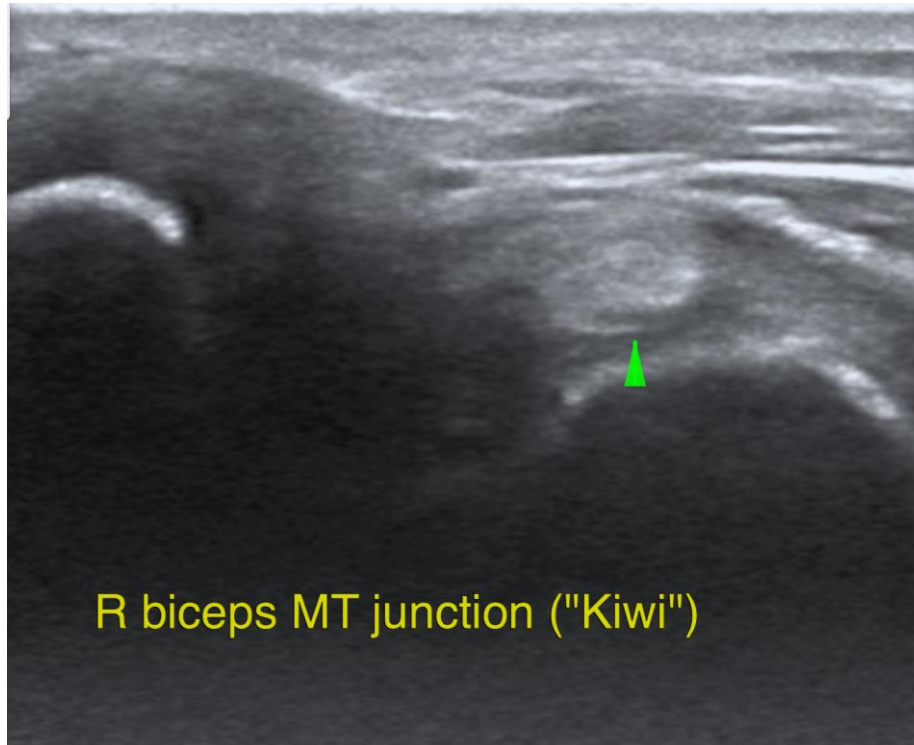
David Lane

INVOICE

54384

DATE

9-30-22





PATIENT

Henry Fleming

The information and recommendations provided are based on the images presented by the referring veterinarian/sonographer. No evaluation can be communicated regarding pathology that was not visible in the image/video clips provided.

Thank you for this referral. If the clinical or image interpretation does not parallel your findings or if I can be of any further assistance please contact me.

SPECIES

Canine

Nele Eley, DVM, Dr. med. vet., DipECVDI
European Specialist in Veterinary Diagnostic Imaging, Cert. Radiology,
Senior lecturer University of Giessen, Germany, Veterinary Faculty, Department of Radiology
Nele.Eley@sonopath.com

BREED

Pitbull X

SEX

MN

AGE

6 Years

INTERPRETED BY

Nele Eley, DVM
Dr. med. Vet. DipECVDI

HOSPITAL NAME

Points East West
Veterinary Services

REFERRING VET

David Lane

INVOICE

54384

DATE

9-30-22