

**PATIENT**Diamond Taylor
Muldrew**PRESENTING CLINICAL SIGNS**

Presented for standard COHAT. Extracted 210, 206, 209, and 411 after CT.

COMPUTED TOMOGRAPHIC STUDY OF THE DENTAL ARCADES**SPECIES**

Canine

Plain study available for review.

BREED

Maltese

COMPUTED TOMOGRAPHIC FINDINGS

The dentition is incomplete. Multiple teeth are absent. The following teeth are remaining: 102, 103, 104, 108, 109, 110, 203, 204, 206, 208, 209, 210, 301, 304, 305, 306, 307, 308, 309, 310, 311, 401, 404, root remnant of 405, 406, 407, 408, 409, 410, 411.

Regional destructive rhinitis and loss of the lateral cortical outline of the maxillary bone is seen level with the dental root of the Triadan 104.

SEX

FS

Multifocal dental plaques are seen.

Vertical bone loss is associated with the Triadans 209 and 210.

AGE

12 Years

Resorptive lesions of the tooth root of the Triadan 408 are seen.

Moderate to severe horizontal atrophy of the alveolar crest is seen in all quadrants of the jaw.

INTERPRETED BYNele Eley, DVM
Dr. med. Vet. DipECVDI**COMPUTED TOMOGRAPHIC DIAGNOSIS**

- Incomplete dentition with periodontal disease and alveolar crest atrophy - periodontal disease, based on the CT findings, accentuates the Triadans 209, 210, 408
- Small dental fistula.
- Regionally destructive rhinitis Triadan 104.

HOSPITAL NAMESouth Bay Animal
Hospital & Pet Resort**INTERPRETATION OF THE FINDINGS & FURTHER RECOMMENDATIONS**

Multifocal periodontal disease is noted. There is a fistula formation and regionally destructive rhinitis of the Triadan 104 which, however, may not be clinically significant yet. The CT changes need to be cross referenced with the clinical workup in order to determine the need for extractions.

REFERRING VET

Dr. Ravinder Atwal

INVOICE

47623

DATE

9-30-21



PATIENT

Diamond Taylor
Muldrew

SPECIES

Canine

BREED

Maltese

SEX

FS

AGE

12 Years

INTERPRETED BY

Nele Eley, DVM
Dr. med. Vet. DipECVDI

HOSPITAL NAME

South Bay Animal
Hospital & Pet Resort

REFERRING VET

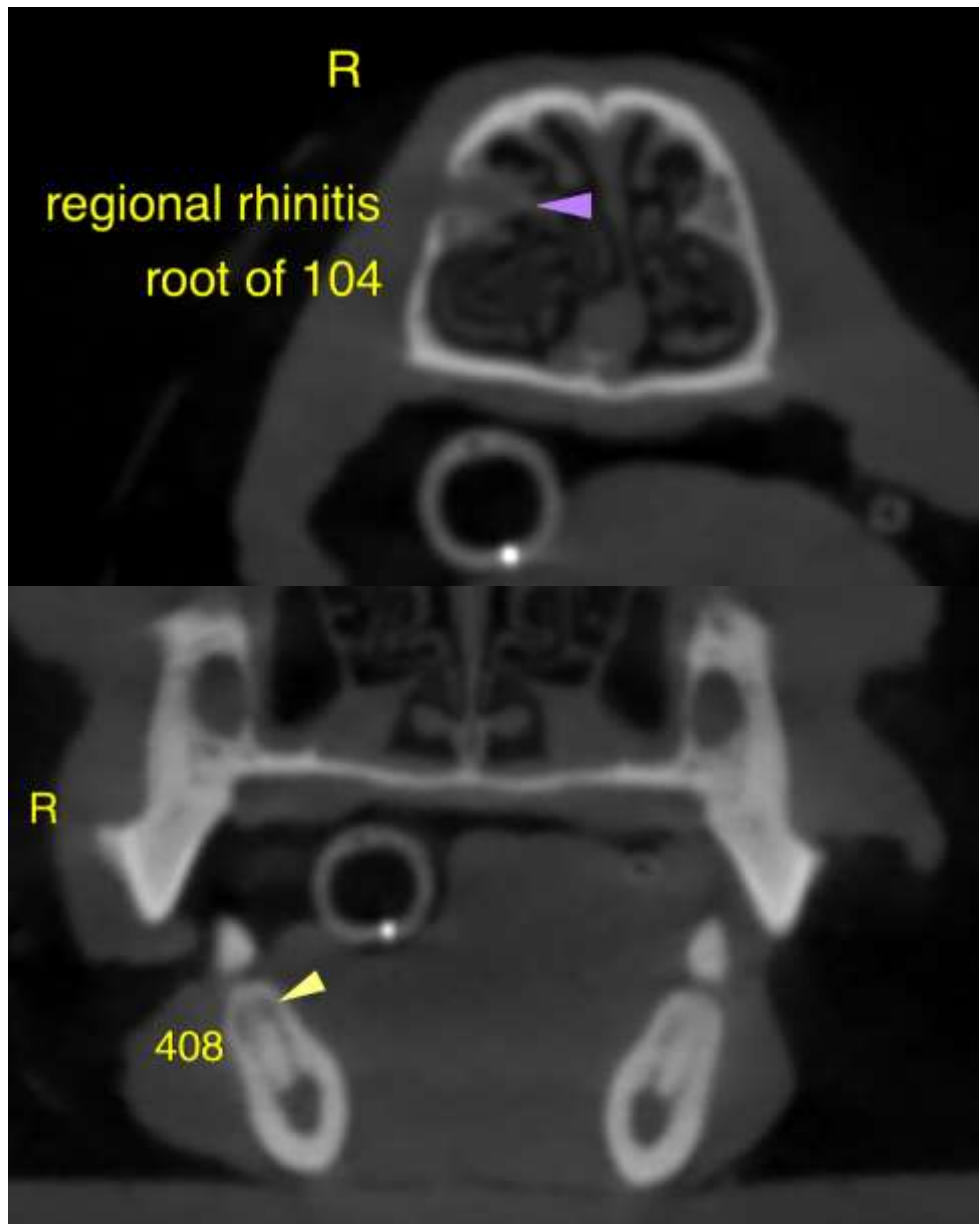
Dr. Ravinder Atwal

INVOICE

47623

DATE

9-30-21





PATIENT

Diamond Taylor
Muldrew

The information and recommendations provided are based on the images presented by the referring veterinarian. No evaluation can be communicated regarding pathology that was not visible in the image/video clips provided.

Thank you for this referral. If the clinical or image interpretation does not parallel your findings or if I can be of any further assistance please contact me.

SPECIES

Canine

Nele Eley, DVM, Dr. med. vet., DipECVDI
European Specialist in Veterinary Diagnostic Imaging, Cert. Radiology,
Senior lecturer University of Giessen, Germany, Veterinary Faculty, Department of Radiology
Nele.Eley@sonopath.com

BREED

Maltese

SEX

FS

AGE

12 Years

INTERPRETED BY

Nele Eley, DVM
Dr. med. Vet. DipECVDI

HOSPITAL NAME

South Bay Animal
Hospital & Pet Resort

REFERRING VET

Dr. Ravinder Atwal

INVOICE

47623

DATE

9-30-21