



PATIENT

Tasha Kadavy

PRESENTING CLINICAL SIGNS

Noted weight loss over the last 4 weeks -- minor left fore-limb lameness progressing to near non-weight placement with recheck today despite use of Galiprant then adding Gabapentin. Imaging today as a means of evaluation - concerns for underlying neoplasia. Recent labs with minor age changes -- added thorax with concerns for neoplasia and weight loss
 Abnormal PE/Chem/CBC/UA Results: rising liver values increased TRI despite weight loss no overt disease signals

SPECIES

Canine

BREED

Bichon Frise

RADIOGRAPHIC STUDY OF THE SHOULDERS & THORAX

Mediolateral views of both shoulders and right/left lateral and ventrodorsal views of the thorax totaling 3 images available for review.

RADIOGRAPHIC FINDINGS

SEX

FS

Shoulders

The left shoulder presents within normal age related limits.

Mild osteophytosis of the right humeral head is noted.

AGE

14 Years, 2 Months

The intervertebral disc space C6/7 is moderately reduced in width and vertebral end plate sclerosis as well as spondylosis deformans are noted.

INTERPRETED BY

Nele Eley, DVM
 Dr. med. Vet. DipECVDI

C7 presents two vestigial ribs. The left vestigial rib of C7 is fused to the 1st left regular rib.

Thorax

Moderate collapse of the caudal cervical trachea is noted.

HOSPITAL NAME

Gentle Doctor Animal Hospital

There is no radiographic evidence of cardiovascular pathology. The vertebral heart score is 9.8.

The lung and bronchial tree are considered within age related normal limits. No evidence of pulmonary nodules or masses is seen.

There is no evidence of abnormal mediastinal widening.

REFERRING VET

Dr. Bashara

RADIOGRAPHIC DIAGNOSIS

- Mild right shoulder osteoarthritis.
- Radiographically normal left shoulder.
- Chronic intervertebral disc disease within the deep cervical spine between C6 and C7.
- Vestigial ribs of C7 – incidental finding.
- Normal age related thorax except for evidence of dynamic tracheal disease.

INVOICE

53926

DATE

9-3-22



PATIENT

Tasha Kadavy

INTERPRETATION OF THE FINDINGS & FURTHER RECOMMENDATIONS

No signs of neoplasia are seen in the radiographic study of the thorax.

SPECIES

Canine

The left shoulder presents within normal radiographic limits. Mild right shoulder osteoarthritis is seen and of uncertain clinical significance.

BREED

Bichon Frise

Note the presence of chronic intervertebral disc disease within the deep cervical spine between C6 and C7 which may correlate with the patient's clinical signs. However, cross sectional imaging may be required in order to rule out potential differential diagnoses.

SEX

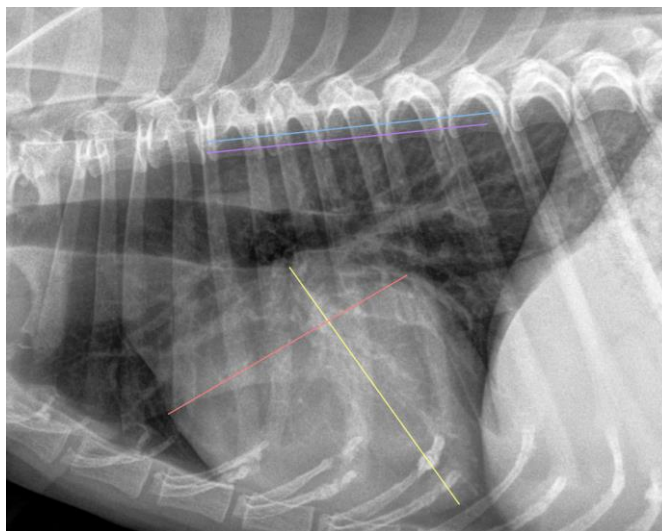
FS

AGE

14 Years, 2 Months

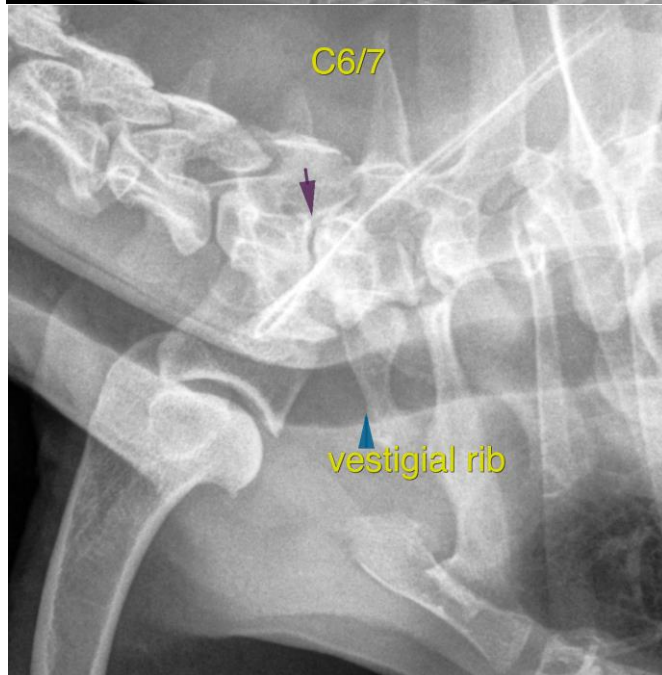
INTERPRETED BY

Nele Eley, DVM
Dr. med. Vet. DipECVDI



HOSPITAL NAME

Gentle Doctor Animal
Hospital



REFERRING VET

Dr. Bashara

INVOICE

53926

DATE

9-3-22



PATIENT

Tasha Kadavy

The information and recommendations provided are based on the images presented by the referring veterinarian/sonographer. No evaluation can be communicated regarding pathology that was not visible in the image/video clips provided.

SPECIES

Canine

Thank you for this referral. If the clinical or image interpretation does not parallel your findings or if I can be of any further assistance please contact me.

BREED

Bichon Frise

Nele Eley, DVM, Dr. med. vet., DipECVDI
European Specialist in Veterinary Diagnostic Imaging, Cert. Radiology,
Senior lecturer University of Giessen, Germany, Veterinary Faculty, Department of Radiology
Nele.Eley@sonopath.com

SEX

FS

AGE

14 Years, 2 Months

INTERPRETED BY

Nele Eley, DVM
Dr. med. Vet. DipECVDI

HOSPITAL NAME

Gentle Doctor Animal
Hospital

REFERRING VET

Dr. Bashara

INVOICE

53926

DATE

9-3-22