

**PATIENT**

Nala Imes

PRESENTING CLINICAL SIGNS

Patient presented for intermittent non weight bearing on right pelvic limb, was started on galliprant 2 weeks ago but still has pain

Abnormal PE/Chem/CBC/UA Results: Moderate muscle atrophy on right pelvic limb, decreased ROM, resistant to right hip extension

SPECIES

Canine

RADIOGRAPHIC STUDY OF THE STIFLES & PELVIS

Ventrodorsal and lateral views of the pelvis and mediolateral views of the stifles totaling 6 images available for review.

BREED

Bulldog

RADIOGRAPHIC FINDINGS

Severe vertebral end plate sclerosis and spondylosis deformans are seen at the lumbosacral junction.

SEX

FS

T13/L1, L1/2, L2/3, L4/5 present varying degrees of spondylosis deformans.

The stifles present within normal limits.

AGE

12 Years

Mild atrophy of the left hind limb musculature appears to be present when compared with the right side. However, part of this may be attributable to the different positioning of the right and left hind limb.

INTERPRETED BY

Nele Eley, DVM
Dr. med. Vet. DipECVDI

Both coxofemoral joints show signs of mild dysplasia with mild secondary coxofemoral joint osteoarthritis.

RADIOGRAPHIC DIAGNOSIS

- Mild bilateral canine hip dysplasia with mild secondary coxofemoral joint osteoarthritis.
- Possible mild atrophy of the musculature of the left hind limb.
- Normal radiographic presentation of the stifle joints.
- Severe degenerative lumbosacral stenosis.

HOSPITAL NAME

Boca Park Animal
Hospital

INTERPRETATION OF THE FINDINGS & FURTHER RECOMMENDATIONS**REFERRING VET**

Dr. Corinna Gorgon

The nature and degree of the changes of the coxofemoral joints does not to fully explain the clinical presentation of the patient and differential diagnoses such as lumbosacral disease including cauda equina syndrome, foraminal stenosis, and other pathologies should be considered. Further definition may require cross sectional imaging and in this context, ideally an MRI.

INVOICE

53928

DATE

9-3-22



PATIENT

Nala Imes

SPECIES

Canine

BREED

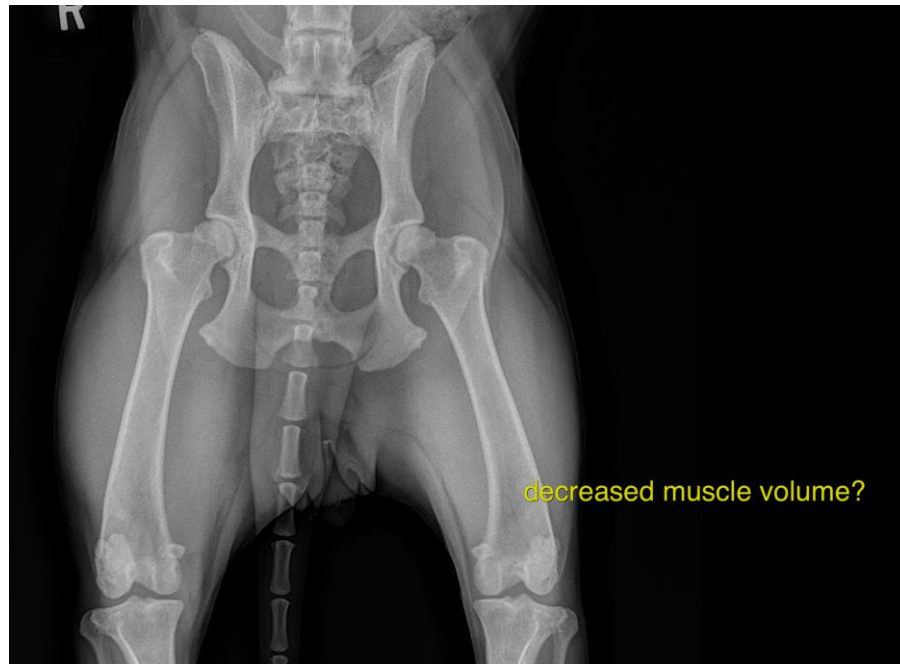
Bulldog

SEX

FS

AGE

12 Years



INTERPRETED BY

Nele Eley, DVM
Dr. med. Vet. DipECVDI

The information and recommendations provided are based on the images presented by the referring veterinarian/sonographer. No evaluation can be communicated regarding pathology that was not visible in the image/video clips provided.

Thank you for this referral. If the clinical or image interpretation does not parallel your findings or if I can be of any further assistance please contact me.

HOSPITAL NAME

Boca Park Animal
Hospital

Nele Eley, DVM, Dr. med. vet., DipECVDI
European Specialist in Veterinary Diagnostic Imaging, Cert. Radiology,
Senior lecturer University of Giessen, Germany, Veterinary Faculty, Department of Radiology
Nele.Eley@sonopath.com

REFERRING VET

Dr. Corinna Gorgon

INVOICE

53928

DATE

9-3-22