



**PATIENT**

Ghost Face Killah  
Hamilton

**PRESENTING CLINICAL SIGNS**

Coughing since early August, progressive worsening since August. Occasional eye discharge. All else is normal. Felv/FIV snap negative. Bartonella pending.

**SPECIES**

Feline

**RADIOGRAPHIC STUDY OF THE THORAX**

Right/left lateral and ventrodorsal views of the thorax totaling 4 images available for review.

**BREED**

DSH

**RADIOGRAPHIC FINDINGS**

The degree of pulmonary inflation is moderate. A moderate multifocal peribronchial interstitial infiltrate with underlying bronchial lung pattern and peribronchial cuffing is seen accentuating the caudodorsal lung.

**SEX**

Male Neutered

Course and width of the trachea are considered within normal limits.

There is no evidence of mediastinal lymphadenomegaly or pleural effusion.

The cardiovascular structures present within normal limits.

**AGE**

1 Year

**RADIOGRAPHIC DIAGNOSIS**

- Bronchial pattern and multifocal peribronchial infiltrate accentuated caudodorsally.

**INTERPRETED BY**

Nele Eley, DVM  
Dr. med. Vet. DipECVDI

**INTERPRETATION OF THE FINDINGS & FURTHER RECOMMENDATIONS**

The radiographic study reveals evidence of active lower airway disease. Infectious bronchitis such as viral, bacterial, parasitic, or protozoal is considered likely. Allergic lower airway syndrome is a potential but less likely differential diagnosis owing to the radiographic presentation and distribution of the changes. Consider a clinical trial of treatment for bronchitis including deworming the patient versus further definition by means of airway sampling.

**HOSPITAL NAME**

Ramapo Valley  
Animal Hospital

**REFERRING VET**

Manohar Katara, dvm

**INVOICE**

54369

**DATE**

9-29-22



**PATIENT**

Ghost Face Killah  
Hamilton

**SPECIES**

Feline

**BREED**

DSH

**SEX**

Male Neutered

**AGE**

1 Year

**INTERPRETED BY**

Nele Eley, DVM  
Dr. med. Vet. DipECVDI

**HOSPITAL NAME**

Ramapo Valley  
Animal Hospital

**REFERRING VET**

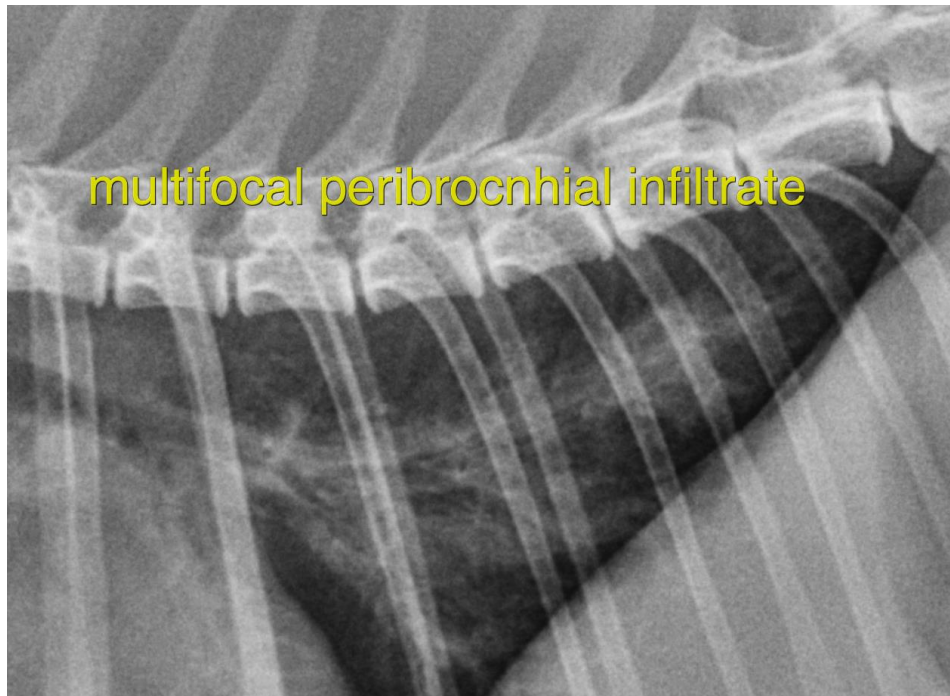
Manohar Katara, dvm

**INVOICE**

54369

**DATE**

9-29-22



The information and recommendations provided are based on the images presented by the referring veterinarian/sonographer. No evaluation can be communicated regarding pathology that was not visible in the image/video clips provided.

Thank you for this referral. If the clinical or image interpretation does not parallel your findings or if I can be of any further assistance please contact me.

**Nele Eley, DVM, Dr. med. vet., DipECVDI**  
European Specialist in Veterinary Diagnostic Imaging, Cert. Radiology,  
Senior lecturer University of Giessen, Germany, Veterinary Faculty, Department of Radiology  
Nele.Eley@sonopath.com