



PATIENT

Kimberly White

PRESENTING CLINICAL SIGNS

Mass on chest, Started growing rapidly

SPECIES

Canine

COMPUTED TOMOGRAPHIC STUDY OF THE THORAX

Plain study available for review. The caudal aspect of the thorax is not fully included and there is no post-contrast study available.

Please consider obtaining a post-contrast study for all cases with potential soft tissue pathology.

BREED

Lab

COMPUTED TOMOGRAPHIC FINDINGS

The cranial and ventral mediastinum appears to be occupied by a soft tissue attenuating mass. Further characterization of the type of mass is limited to the availability of a plain study.

SEX

MN

A moderate amount of pleural fluid is seen in the dependent portion of both pleural cavities. The lung margins are retracted from the thoracic wall and rounded.

Multiple soft tissue attenuating nodules are seen throughout the parenchyma of all lung lobes.

AGE

5

There appears to be a soft tissue attenuating mass in the left caudal and dorsal thoracic wall which, however, is not fully included in the scan.

COMPUTED TOMOGRAPHIC DIAGNOSIS

- Cranial and ventral mediastinal soft tissue mass.
- Bilaterally symmetric moderate pleural effusion.
- Multiple interstitial pulmonary nodules.
- Suspect soft tissue mass in the left thoracic wall.

INTERPRETED BY

Nele Eley, DVM
Dr. med. Vet. DipECVDI

HOSPITAL NAME

Wilvet Salem

INTERPRETATION OF THE FINDINGS & FURTHER RECOMMENDATIONS

The assessment is limited to the availability of a plain study; however, synthesizing the findings, cranial and ventral mediastinal neoplasia with pulmonary metastatic disease and paraneoplastic effusion / carcinomatosis appears to be a likely potential in this patient. Mediastinal abscess, cyst, hematoma, or other is thought less likely but cannot be ruled out entirely.

REFERRING VET

Anna Wepprick

Theoretical differential diagnosis for the pulmonary nodules is granulomatous neoplasia/pulmonary abscesses with pyothorax/pleuropneumonia which, however, is thought less likely.

INVOICE

47591

Consider aspiration and analysis of the fluid for further definition as well as sampling of the cranioventral mediastinal mass which may be performed under ultrasonographic guidance using a parasternal approach or through the cranial thoracic aperture.

DATE

9-29-21

The esophageal dilation seen may well be due to general anesthesia and does not necessarily represent megaesophagus or other pathological dilation.



PATIENT

Kimberly White

SPECIES

Canine

BREED

Lab

SEX

MN

AGE

5

INTERPRETED BY

Nele Eley, DVM
Dr. med. Vet. DipECVDI

HOSPITAL NAME

Wilvet Salem

REFERRING VET

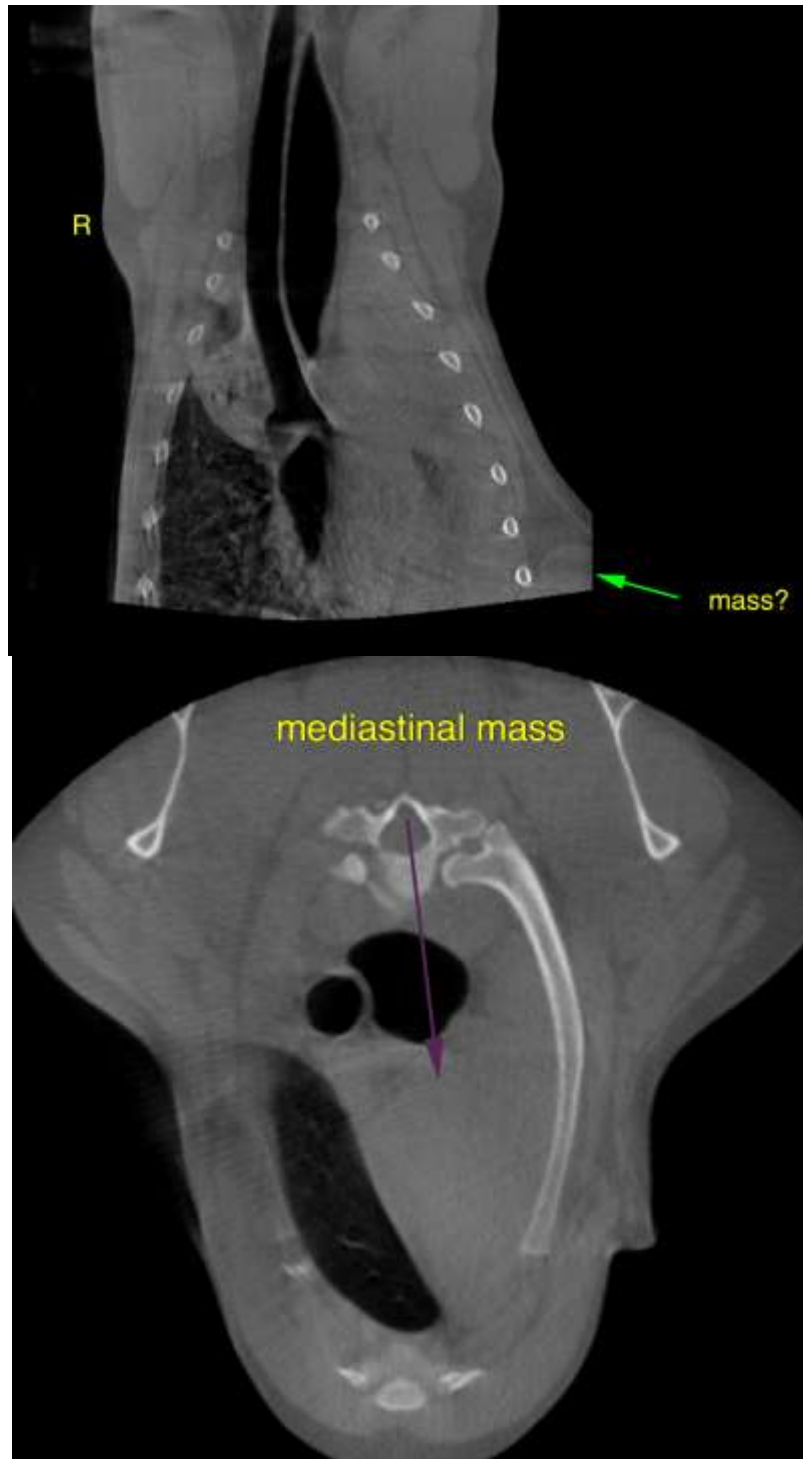
Anna Wepprick

INVOICE

47591

DATE

9-29-21





PATIENT

Kimberly White

SPECIES

Canine

BREED

Lab

SEX

MN

AGE

5

INTERPRETED BY

Nele Eley, DVM
Dr. med. Vet. DipECVDI

HOSPITAL NAME

Wilvet Salem

REFERRING VET

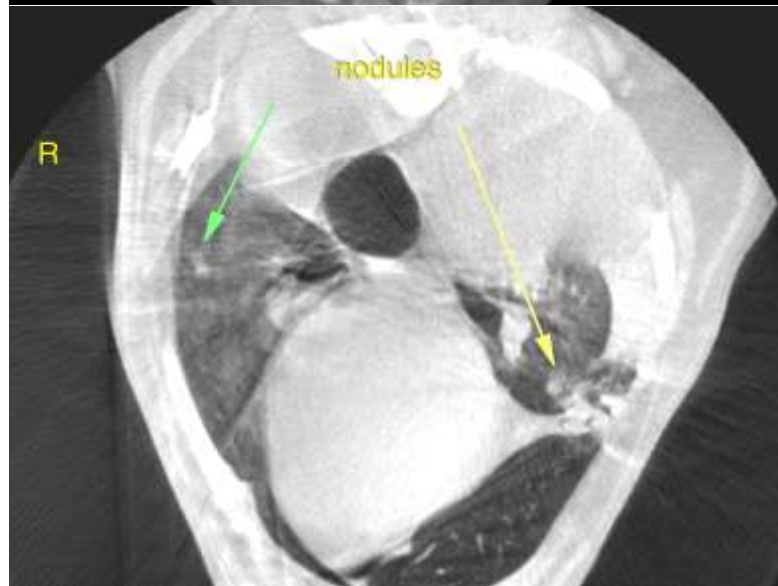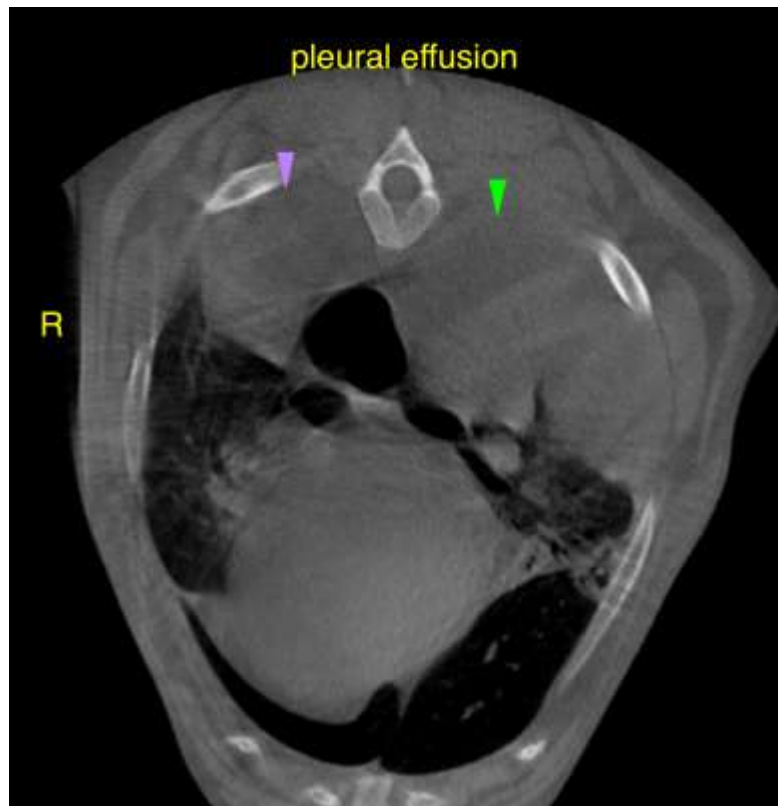Anna Wepprick

INVOICE

47591

DATE

9-29-21





PATIENT

Kimberly White

The information and recommendations provided are based on the images presented by the referring veterinarian. No evaluation can be communicated regarding pathology that was not visible in the image/video clips provided.

Thank you for this referral. If the clinical or image interpretation does not parallel your findings or if I can be of any further assistance please contact me.

SPECIES

Canine

Nele Eley, DVM, Dr. med. vet., DipECVDI
European Specialist in Veterinary Diagnostic Imaging, Cert. Radiology,
Senior lecturer University of Giessen, Germany, Veterinary Faculty, Department of Radiology
Nele.Eley@sonopath.com

BREED

Lab

SEX

MN

AGE

5

INTERPRETED BY

Nele Eley, DVM
Dr. med. Vet. DipECVDI

HOSPITAL NAME

Wilvet Salem

REFERRING VET

Anna Wepprick

INVOICE

47591

DATE

9-29-21