



PATIENT

Gracie Templeton

PRESENTING CLINICAL SIGNS

P was lost for a month, brought in by a good samaritan who found the p and noticed an oral mass on the mandible. When returned to O, O stated he thinks p must have gotten under his car and that's how p was lost and believes this is the origin of the mass (ie from injury). Mass itself is proliferative and takes up the entirety of the front portion of the mandible eroding the incisors and canines. There is tissue loss and exposed bone on the lateral aspect of the left mandible. P is feeling fine and is eating and drinking. Sending out punch biopsy. FELV/FIV/HW neg

SPECIES

Feline

COMPUTED TOMOGRAPHIC STUDY OF THE HEAD

BREED

Plain and post contrast studies available for review.

DSH

COMPUTED TOMOGRAPHIC FINDINGS

SEX

Irregular soft tissue swelling is seen ventral and rostral of both mandibles. Incomplete loss of the soft tissue lateral of the left mandible is present.

SF

There is a cavitating lesion with peripheral rim enhancement of approximately 1.0 cm diameter between both mandibular bodies ventral of the tongue.

AGE

4 Years

The mandibular incisors are lost. Both mandibular canine teeth present complicated crown fractures. The mandibular symphysis is intact. The ventral cortical bone of the incisor portion of both mandibles is lost.

INTERPRETED BY

Nele Eley, DVM
Dr. med. Vet. DipECVDI

Multiple well delineated osseous defects are seen in the ventral and lateral aspect of the left mandibular body which are partially bridged to the remainder of the mandible by ill-defined bony callus formation. The lateral cortical outline of the left mandible is irregular. The medullary bone presents mild heterogeneous sclerosis. Mild periosteal new bone formation is seen.

There is no evidence of temporomandibular joint or mandibular bone fracture.

HOSPITAL NAME

Animal Medical
Center of Mt.
Pleasant

The occlusion appears to be within normal limits.

Complicated crown fracture of the right maxillary canine teeth is seen.

COMPUTED TOMOGRAPHIC DIAGNOSIS

REFERRING VET

Dr. Tess Lawhon

- Healing multiple superficial mandibular slab fracture with traumatic loss of soft tissue and osteitis.
- Presumed abscess formation between both mandibles - differential diagnosis hematoma with liquefaction.

INVOICE

47594

INTERPRETATION OF THE FINDINGS & FURTHER RECOMMENDATIONS

The CT findings are compatible with the history of traumatic injury of the lower jaws. Superficial slab fractures are seen in the rostral incisor portions of both mandibles. Multiple superficial slab fractures of the lateral cortical bone are seen in the left mandibular body. Part of the small fracture fragments are bridged by callus formation. Sequestrum formation cannot be ruled out in the lateral cortical bone of the mandibular body level with the premolar teeth. There are signs of osteitis with a presumed abscess formation between both mandibles. Differential diagnosis for the cavity lesion is organizing hematoma with liquefaction.

DATE

9-29-21



PATIENT

Gracie Templeton

SPECIES

Feline

BREED

DSH

SEX

SF

AGE

4 Years

INTERPRETED BY

Nele Eley, DVM
Dr. med. Vet. DipECVDI

HOSPITAL NAME

Animal Medical
Center of Mt.
Pleasant

REFERRING VET

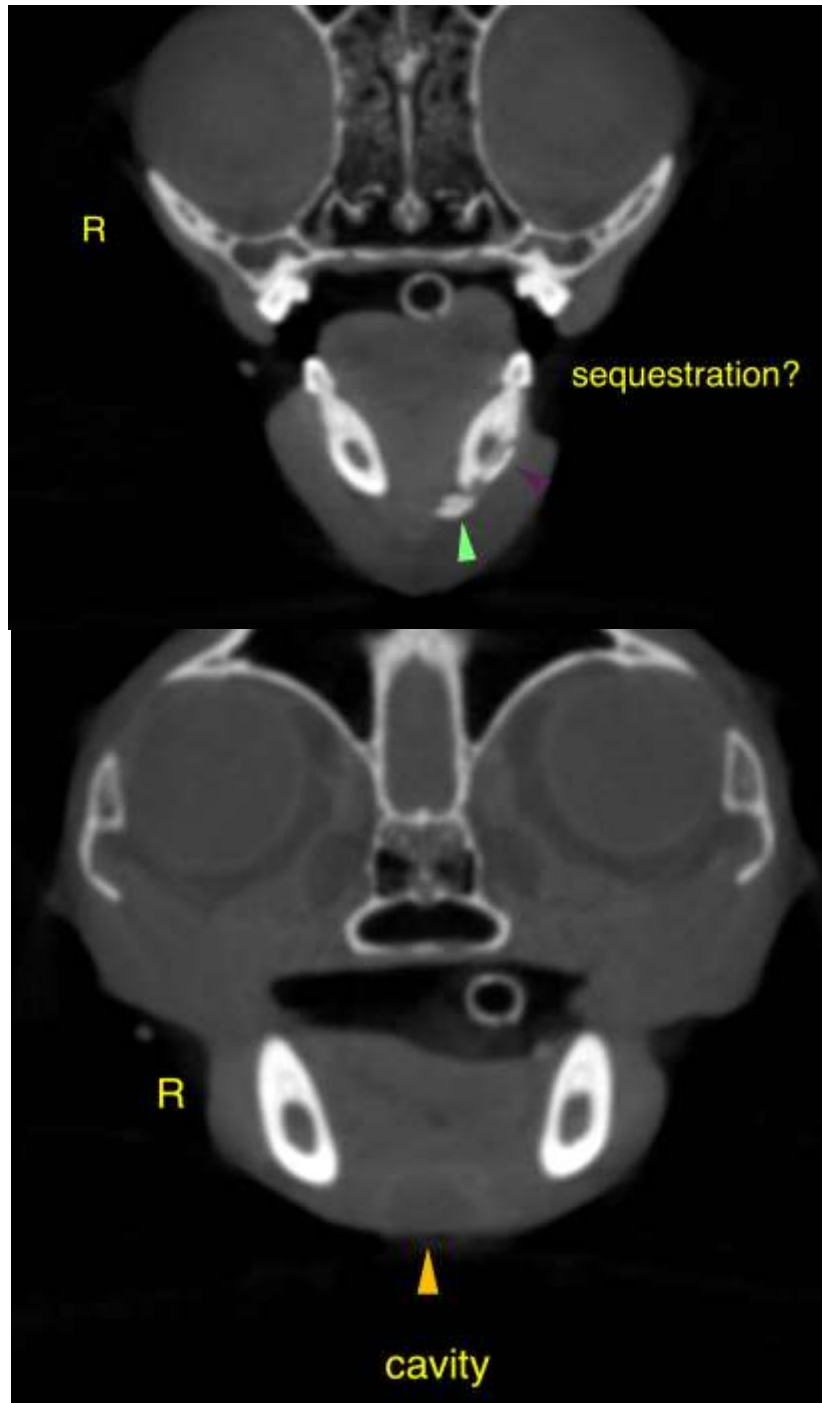
Dr. Tess Lawhon

INVOICE

47594

DATE

9-29-21





PATIENT

Gracie Templeton

The information and recommendations provided are based on the images presented by the referring veterinarian. No evaluation can be communicated regarding pathology that was not visible in the image/video clips provided.

Thank you for this referral. If the clinical or image interpretation does not parallel your findings or if I can be of any further assistance please contact me.

SPECIES

Feline

Nele Eley, DVM, Dr. med. vet., DipECVDI
European Specialist in Veterinary Diagnostic Imaging, Cert. Radiology,
Senior lecturer University of Giessen, Germany, Veterinary Faculty, Department of Radiology
Nele.Eley@sonopath.com

BREED

DSH

SEX

SF

AGE

4 Years

INTERPRETED BY

Nele Eley, DVM
Dr. med. Vet. DipECVDI

HOSPITAL NAME

Animal Medical
Center of Mt.
Pleasant

REFERRING VET

Dr. Tess Lawhon

INVOICE

47594

DATE

9-29-21