



PATIENT

Emmett Harris

PRESENTING CLINICAL SIGNS

Patient has chronic heart issues. Was first diagnosed on 8/4/21. He has mitral valve disease and pulmonary edema. The right lateral was taken after patient had sat for 4-5 hours in an oxygen chamber. The other two x-rays are prior to being in the oxygen tank. Upon examination prior to the oxygen tank patient had SYSTOLIC MURMUR. INCREASED RESP RAT AND EFFORT. Otherwise normal.

SPECIES

Canine

Abnormal PE/Chem/CBC/UA Results: n/a

BREED

Bichon Frise

RADIOGRAPHIC STUDY OF THE THORAX

Right/left lateral and ventrodorsal views totaling 3 images available for review.

RADIOGRAPHIC FINDINGS

SEX

MN

The lungs are better aerated on the right lateral view which had been obtained after prolonged oxygen administration. However, a moderate regional mixed pulmonary infiltrate accentuating the perihilar and caudoventral lung is seen on both studies.

AGE

14 Years, 9 Months

Moderate left sided cardiomegaly with left atrial tenting and loss of the caudal cardiac waist is seen. The trachea is mildly elevated. The pulmonary veins appear to be dilated. The vertebral heart score is 10.6.

Mild aerophagia is seen.

INTERPRETED BY

Nele Eley, DVM
Dr. med. Vet. DipECVDI

There is mild bilateral shoulder osteoarthritis as well as bilateral elbow osteoarthritis noted.

RADIOGRAPHIC DIAGNOSIS

- Moderate left sided cardiomegaly with presumed cardiogenic pulmonary edema.

HOSPITAL NAME

Elizabeth Animal Hospital

INTERPRETATION OF THE FINDINGS & FURTHER RECOMMENDATIONS

The radiographic findings are compatible with moderate left sided cardiomegaly. Myxomatous mitral valve degeneration with chronic mitral valve regurgitation is considered the most likely underlying cause.

REFERRING VET

Leon Anderson, DVM

The pulmonary changes are highly suggestive for cardiogenic pulmonary edema. A noncardiogenic component in terms of acute respiratory distress syndrome may be present concurrently. Consider further stabilization as necessary and the use of diuretics in this patient. A more detailed staging of the cardiac disease would require a cardiac echo.

INVOICE

47602

DATE

9-29-21



PATIENT

Emmett Harris

SPECIES

Canine

BREED

Bichon Frise

SEX

MN

AGE

14 Years, 9 Months

INTERPRETED BY

Nele Eley, DVM
Dr. med. Vet. DipECVDI

HOSPITAL NAME

Elizabeth Animal
Hospital

REFERRING VET

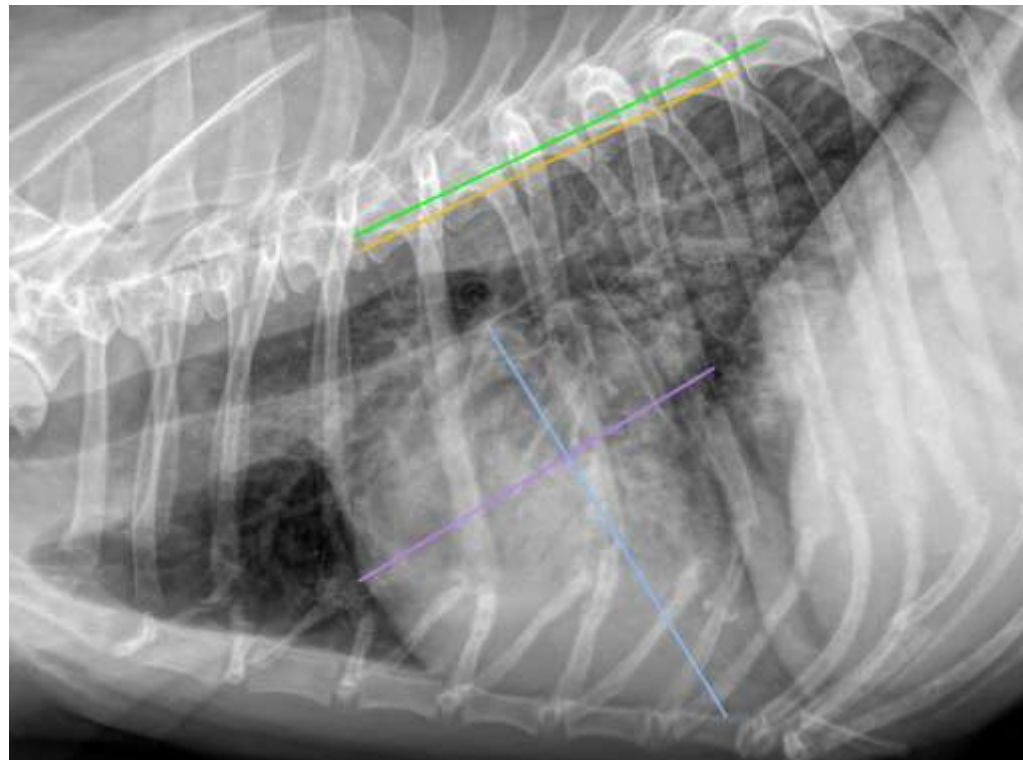
Leon Anderson, DVM

INVOICE

47602

DATE

9-29-21



The information and recommendations provided are based on the images presented by the referring veterinarian. No evaluation can be communicated regarding pathology that was not visible in the image/video clips provided.

Thank you for this referral. If the clinical or image interpretation does not parallel your findings or if I can be of any further assistance please contact me.

Nele Eley, DVM, Dr. med. vet., DipECVDI
European Specialist in Veterinary Diagnostic Imaging, Cert. Radiology,
Senior lecturer University of Giessen, Germany, Veterinary Faculty, Department of Radiology
Nele.Eley@sonopath.com