



PATIENT

Flower Archer

PRESENTING CLINICAL SIGNS

Pt has been sneezing and coughing for the majority of the summer, but o thought it was allergies. Pt has a hx soft, growth under chin that o noted has been growing. BW/UA/cytology of growth pending.

SPECIES

Canine

RADIOGRAPHIC STUDY OF THE THORAX

Right/left lateral and ventrodorsal views of the thorax totaling 3 images available for review.

BREED

Shih Tzu

RADIOGRAPHIC FINDINGS

There is severe tracheal collapse of the mid and caudal cervical trachea on the right lateral view. The degree of collapse is less severe on the left lateral view. No evidence of concurrent bronchial collapse is noted.

SEX

SF

The bronchial tree presents mild generalized wall enhancement with no significant peribronchial cuffing.

AGE

15 Years

The cardiac silhouette presents mild cranial rotation with prominence of the aortic arch which is a normal age related finding. No specific chamber enlargement is noted. The vertebral heart score is within normal limits with 9.5.

No evidence of abnormal mediastinal widening is noted.

INTERPRETED BY

Nele Eley, DVM
Dr. med. Vet. DipECVDI

There appears to be soft tissue swelling in the submandibular area. Correlate with the clinical palpation.

Moderate gastric aerophagia is noted.

HOSPITAL NAME

The Pet Hospital of
Stratford

RADIOGRAPHIC DIAGNOSIS

- Dynamic tracheal disease with severely collapsing cervical trachea.
- Normal age related findings of the lung.
- No evidence of cardiovascular pathology.

REFERRING VET

Dr. Giuliani

INTERPRETATION OF THE FINDINGS & FURTHER RECOMMENDATIONS

The radiographic study reveals evidence of dynamic tracheal disease with severely collapsing mid and caudal cervical trachea. Further evaluation of the airway by means of endoscopy could be considered depending on the severity of the clinical signs in order to determine whether this patient is a potential candidate for tracheal stenting.

INVOICE

54341

The aerophagia is likely secondary to the respiratory distress.

DATE

9-28-22



PATIENT

Flower Archer

SPECIES

Canine

BREED

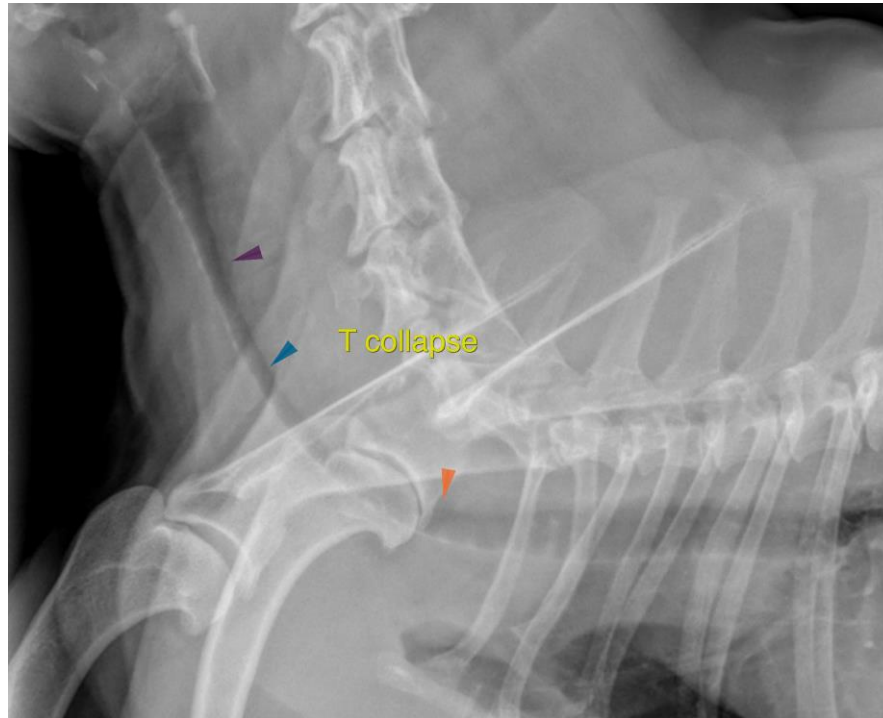
Shih Tzu

SEX

SF

AGE

15 Years



INTERPRETED BY

Nele Eley, DVM
Dr. med. Vet. DipECVDI

The information and recommendations provided are based on the images presented by the referring veterinarian/sonographer. No evaluation can be communicated regarding pathology that was not visible in the image/video clips provided.

HOSPITAL NAME

The Pet Hospital of
Stratford

Thank you for this referral. If the clinical or image interpretation does not parallel your findings or if I can be of any further assistance please contact me.

Nele Eley, DVM, Dr. med. vet., DipECVDI
European Specialist in Veterinary Diagnostic Imaging, Cert. Radiology,
Senior lecturer University of Giessen, Germany, Veterinary Faculty, Department of Radiology
Nele.Eley@sonopath.com

REFERRING VET

Dr. Giuliani

INVOICE

54341

DATE

9-28-22