



PATIENT

Katie Corver

PRESENTING CLINICAL SIGNS

Presented to surgeon due to firm mass at the base of the left ear. CT for surgical planning.

SPECIES

Feline

COMPUTED TOMOGRAPHIC STUDY OF THE HEAD

Plain and post contrast studies available for review.

BREED

DSH

COMPUTED TOMOGRAPHIC FINDINGS

A large, multilobulated ill-defined soft tissue attenuating mass of approximately 3.5 cm diameter is seen ventral of the left external auditory meatus. The mass presents heterogeneous contrast enhancement and is embedded between the mandibular salivary gland and parotid salivary glands ventrally and dorsally. A nodular structure of 1.0 cm diameter is seen caudal of the mass.

SEX

Female Spayed

The pictured parts of the dentition are complete and unremarkable in all jaw quadrants.

The nasal cavity presents the expected aerated spaces between thin & even conchae and turbinates with smooth mucosal lining.

AGE

11 Years

Both temporomandibular joints present congruent joint spaces with even subchondral bone surfaces and are considered within normal limits.

INTERPRETED BY

Nele Eley, DVM
Dr. med. Vet. DipECVDI

The mass ventral of the external auditory meatus causes deviation and compression of the left external auditory meatus which contains a mild amount of hypoattenuating non-contrast enhancing material. The tympanic bullae are aerated, the mucosal lining is not seen, and the bony wall is smooth and thin.

The brain presents no deviation from normal anatomy and symmetry. The brain parenchyma is homogeneous and within normal limits for attenuation and distribution of contrast enhancement. The ventricular system is non-dilated and symmetric.

HOSPITAL NAME

Mobile Pet Imaging

The left medial retropharyngeal lymph node is enlarged with decreased attenuation and heterogeneous contrast enhancement accentuating the periphery. The lymph node diameter is 2.0 cm. The submandibular lymph nodes present within normal limits.

REFERRING VET

Meaux

- Large soft tissue neoplasia ventral of the left external auditory meatus with regional parotid and retropharyngeal lymphadenomegaly and significant mass effect onto the salivary glands.
- Left sided otitis externa.

INVOICE

47578

COMPUTED TOMOGRAPHIC DIAGNOSIS

INTERPRETATION OF THE FINDINGS & FURTHER RECOMMENDATIONS

DATE

9-28-21

The CT findings are compatible with malignant soft tissue neoplasia ventral of the left external auditory meatus with regional metastatic disease to the parotid and medial retropharyngeal lymph nodes. Primarily lymphomatous mass emerging from the parotid lymph nodes cannot be ruled out as well. Other tumor types would include fibrosarcoma, hemangiosarcoma, salivary gland carcinoma, and other. Final diagnosis will require sampling for histology. Consider fine needle aspiration of the parotid and medial retropharyngeal lymph nodes as well.



PATIENT

Katie Corver

The left sided otitis externa is thought to be due to the obstruction of the ear canal. No direct involvement of the ear canal can be seen.

SPECIES

Feline

BREED

DSH

SEX

Female Spayed

AGE

11 Years

INTERPRETED BY

Nele Eley, DVM
Dr. med. Vet. DipECVDI

HOSPITAL NAME

Mobile Pet Imaging

REFERRING VET

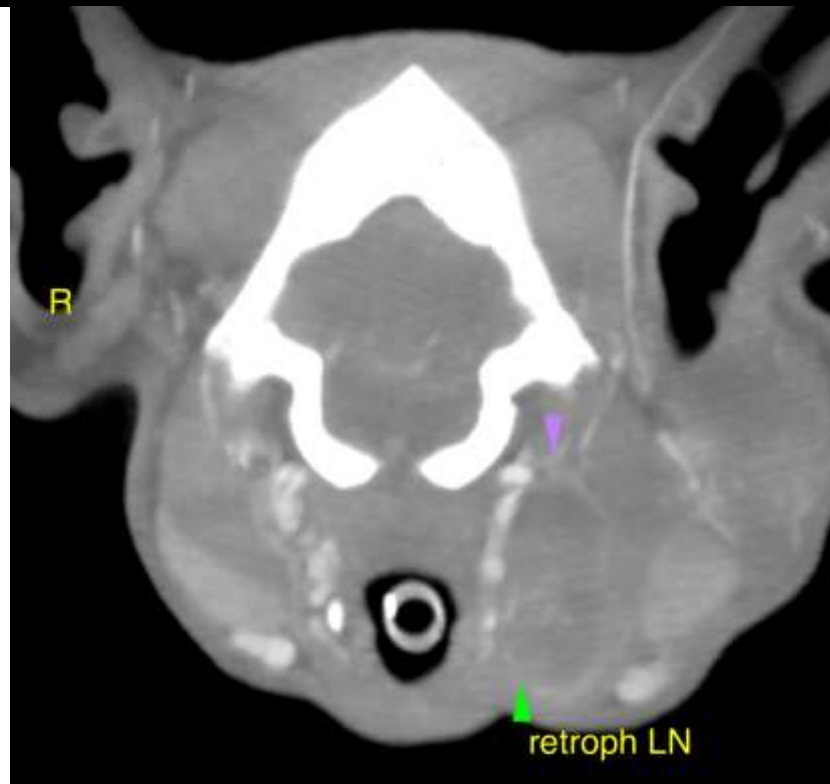
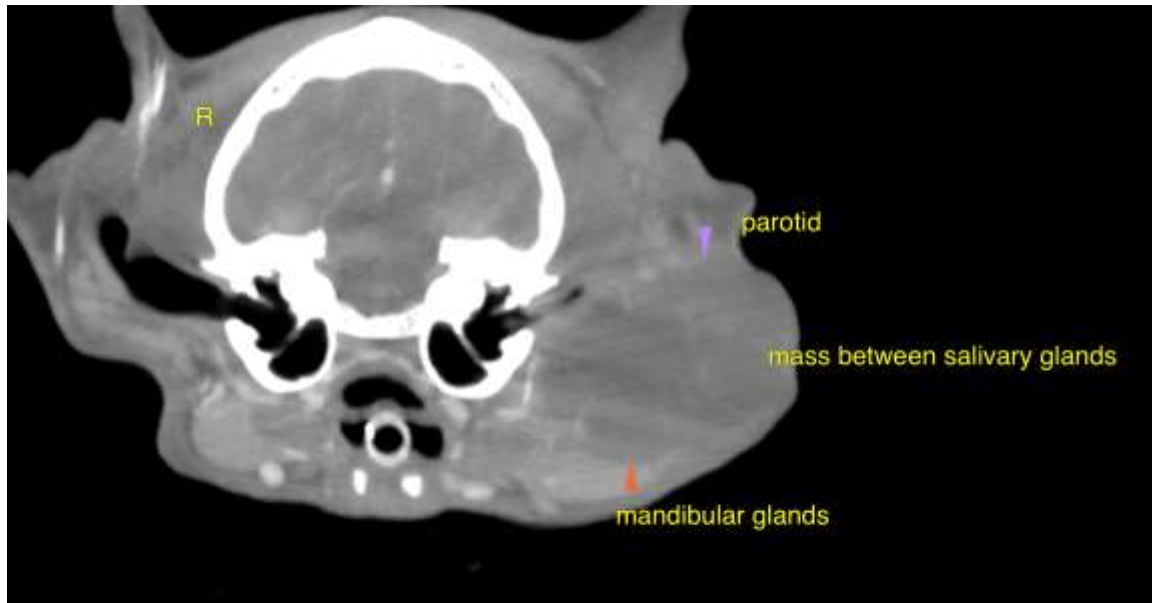
Meaux

INVOICE

47578

DATE

9-28-21





PATIENT

Katie Corver

The information and recommendations provided are based on the images presented by the referring veterinarian. No evaluation can be communicated regarding pathology that was not visible in the image/video clips provided.

SPECIES

Feline

Thank you for this referral. If the clinical or image interpretation does not parallel your findings or if I can be of any further assistance please contact me.

BREED

DSH

Nele Eley, DVM, Dr. med. vet., DipECVDI
European Specialist in Veterinary Diagnostic Imaging, Cert. Radiology,
Senior lecturer University of Giessen, Germany, Veterinary Faculty, Department of Radiology
Nele.Eley@sonopath.com

SEX

Female Spayed

AGE

11 Years

INTERPRETED BY

Nele Eley, DVM
Dr. med. Vet. DipECVDI

HOSPITAL NAME

Mobile Pet Imaging

REFERRING VET

Meaux

INVOICE

47578

DATE

9-28-21