



PATIENT

Johnny Henderson

PRESENTING CLINICAL SIGNS

Bloated abdomen, loose orange-colored stringy stools, and lethargy for about a week. No vomiting, good appetite. History of pancreatitis/gastroenteritis and may have been fed table scraps recently. History of skin allergies and chronic cough.

SPECIES

Canine

Abnormal PE/Chem/CBC/UA Results: 3 inch soft SQ mass ventral abdomen - present for several years. Abdomen palpates "full" and taut cranially. Grade 3 systolic heart murmur and increased bronchovesicular sounds bilaterally. Overweight.

BREED

Yorkshire Terrier Mix

RADIOGRAPHIC STUDY OF THE THORAX & ABDOMEN

Right/left lateral and ventrodorsal whole body views totaling 3 images available for review.

RADIOGRAPHIC FINDINGS

SEX

Spayed Female

Thorax

Moderate left sided cardiomegaly is seen with left atrial tenting and loss of the caudal cardiac waist. The vertebral heart score is 11. No evidence of pulmonary venous congestion and no evidence of cardiogenic pulmonary edema is seen. The trachea is mildly elevated.

AGE

14 Years

Mild redundancy of the dorsal tracheal ligament is noted level with the thoracic inlet.

The lung presents a mild generalized bronchial pattern.

INTERPRETED BY

Nele Eley, DVM
Dr. med. Vet. DipECVDI

Abdomen

The abdominal cavity is voluminous.

A fat opaque subcutaneous mass is seen superimposed onto the ventral abdominal wall.

HOSPITAL NAME

Q Street Animal
Hospital

T13/L1, L4/5, L5/6, L7/S1 spondyloses are noted.

There is stifle osteoarthritis.

Moderate generalized enlargement of the liver appears to be present with slightly rounded lobar margins.

REFERRING VET

Phoebe Cone

There is marked gastrointestinal aerophagia with turgid appearance of the small intestine. No evidence of abnormal intestinal dilation or foreign material is seen.

RADIOGRAPHIC DIAGNOSIS

INVOICE

47583

- Moderate left sided cardiomegaly without evidence of congestive heart failure.
- Redundancy of the dorsal tracheal ligament.
- Moderate hepatomegaly.
- Gastrointestinal aerophagia without radiographic evidence of mechanical ileus.
- Abdominal wall lipoma.
- Multiple spondyloses.
- Stifle osteoarthritis.

DATE

9-28-21



PATIENT

Johnny Henderson

SPECIES

Canine

BREED

Yorkshire Terrier Mix

SEX

Spayed Female

AGE

14 Years

INTERPRETED BY

Nele Eley, DVM
Dr. med. Vet. DipECVDI

HOSPITAL NAME

Q Street Animal
Hospital

REFERRING VET

Phoebe Cone

INVOICE

47583

DATE

9-28-21

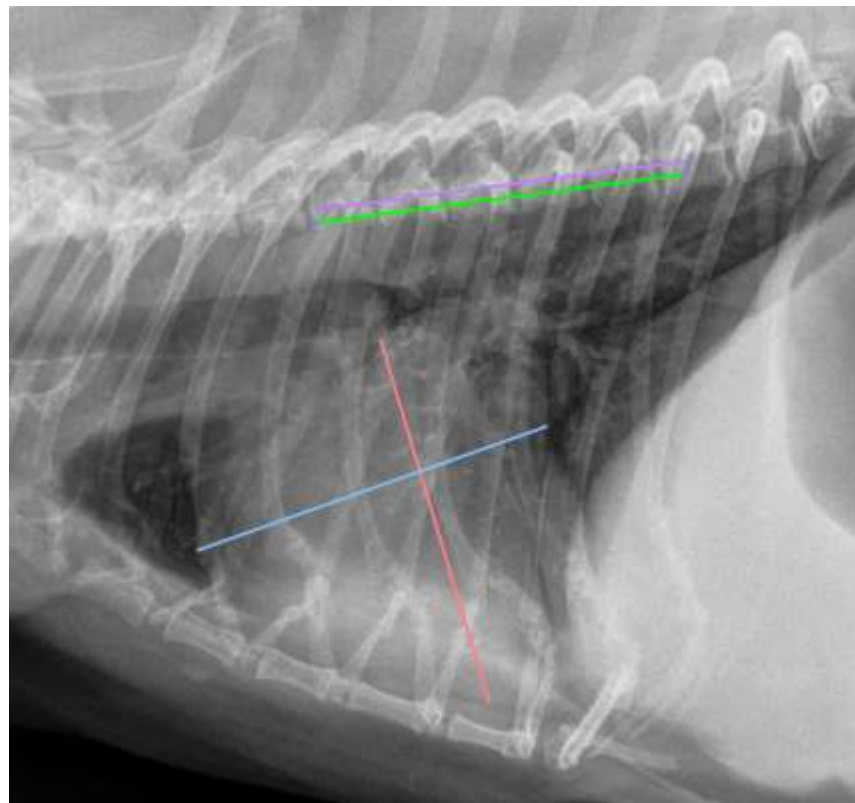
INTERPRETATION OF THE FINDINGS & FURTHER RECOMMENDATIONS

A gastrointestinal maldigestion pattern / gastrointestinal aerophagia are seen. No evidence of mechanical ileus is noted; however, gastroenteropathy is a potential based on the radiographic findings.

Differential diagnosis for the hepatomegaly includes metabolic/endocrine hepatopathy. Diffuse neoplastic or inflammatory infiltrates cannot be ruled out. Correlate with the laboratory values.

Abdominal ultrasound should be considered for further definition in this patient in order to gain more detailed information about the liver, gastrointestinal tract, and other associated organs.

The cardiac changes are considered mild, and no congestive heart failure is seen. Myxomatous mitral valve degeneration with chronic mitral valve regurgitation is thought the most likely underlying cause. A full cardiac echo could be considered for further definition.





PATIENT

Johnny Henderson

The information and recommendations provided are based on the images presented by the referring veterinarian. No evaluation can be communicated regarding pathology that was not visible in the image/video clips provided.

Thank you for this referral. If the clinical or image interpretation does not parallel your findings or if I can be of any further assistance please contact me.

SPECIES

Canine

Nele Eley, DVM, Dr. med. vet., DipECVDI
European Specialist in Veterinary Diagnostic Imaging, Cert. Radiology,
Senior lecturer University of Giessen, Germany, Veterinary Faculty, Department of Radiology
Nele.Eley@sonopath.com

BREED

Yorkshire Terrier Mix

SEX

Spayed Female

AGE

14 Years

INTERPRETED BY

Nele Eley, DVM
Dr. med. Vet. DipECVDI

HOSPITAL NAME

Q Street Animal
Hospital

REFERRING VET

Phoebe Cone

INVOICE

47583

DATE

9-28-21