



PATIENT

Sammy (ODH) Old
Dog Haven

PRESENTING CLINICAL SIGNS

Chronic cough with bronchitis. Crackles on auscultation on exam today.

SPECIES

Canine

RADIOGRAPHIC STUDY OF THE THORAX

Right/left lateral and ventrodorsal views of the thorax totaling 4 images available for review.

BREED

Chihuahua Mix

RADIOGRAPHIC FINDINGS

The degree of pulmonary inflation is fair.

Far cranial excursion of the diaphragm is noted.

There is a moderate generalized bronchial lung pattern with occasional peribronchial cuffing and cylindrical bronchiectasis.

SEX

Spayed Female

Course and width of the trachea are considered within normal limits.

There is no evidence of mediastinal widening.

AGE

14 Years, 8 Months

The vertebral heart score is 9.4. No evidence of cardiovascular pathology is seen.

There is mild esophageal aerophagia which is an incidental finding.

Thoracolumbar spondyloses are noted.

INTERPRETED BY

Nele Eley, DVM
Dr. med. Vet. DipECVDI

RADIOGRAPHIC DIAGNOSIS

- Moderate chronic bronchial lung pattern with early cylindrical bronchiectasis.
- Spondyloses.

HOSPITAL NAME

All Creatures Animal
Hospital of South Hill,
Inc.

INTERPRETATION OF THE FINDINGS & FURTHER RECOMMENDATIONS

The radiographic study reveals a moderate bronchial lung pattern with early cylindrical bronchiectasis. Chronic lower airway disease such as eosinophilic bronchopneumopathy or infectious bronchitis including viral, bacterial, and parasitic as well as irritant bronchitis are potential underlying causes of the patient's clinical signs. Airway endoscopy with airway sampling would be ideal for further definition. If this is not an option, empirical management for bronchitis could be considered alternatively.

REFERRING VET

Dr. Jacquie Preston

INVOICE

54324

DATE

9-27-22



PATIENT

Sammy (ODH) Old
Dog Haven

SPECIES

Canine

BREED

Chihuahua Mix

SEX

Spayed Female

AGE

14 Years, 8 Months

INTERPRETED BY

Nele Eley, DVM
Dr. med. Vet. DipECVDI

HOSPITAL NAME

All Creatures Animal
Hospital of South Hill,
Inc.

REFERRING VET

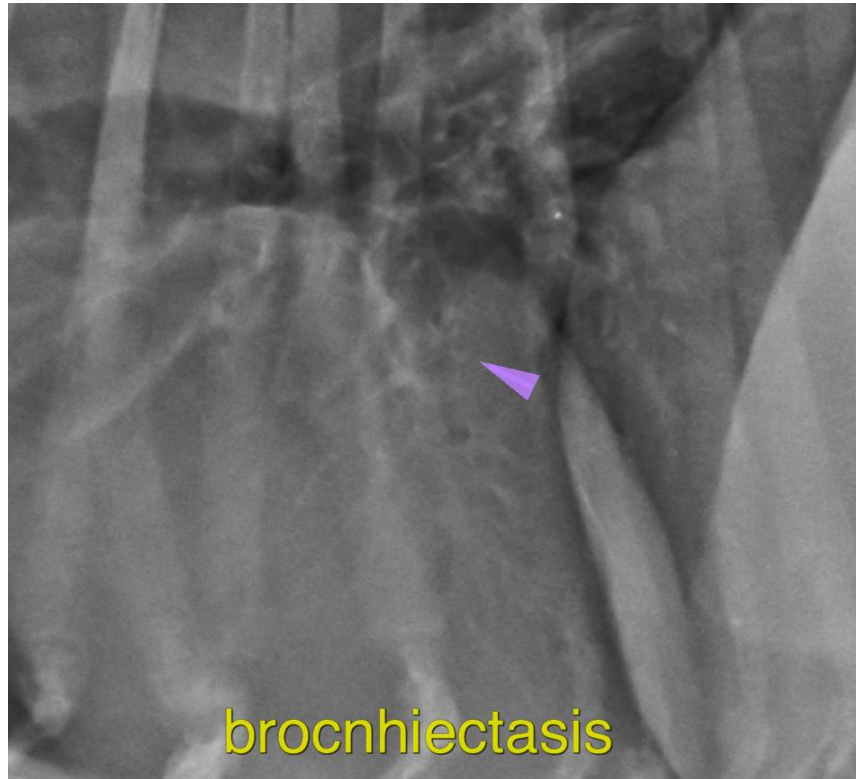
Dr. Jacquie Preston

INVOICE

54324

DATE

9-27-22



The information and recommendations provided are based on the images presented by the referring veterinarian/sonographer. No evaluation can be communicated regarding pathology that was not visible in the image/video clips provided.

Thank you for this referral. If the clinical or image interpretation does not parallel your findings or if I can be of any further assistance please contact me.

Nele Eley, DVM, Dr. med. vet., DipECVDI
European Specialist in Veterinary Diagnostic Imaging, Cert. Radiology,
Senior lecturer University of Giessen, Germany, Veterinary Faculty, Department of Radiology
Nele.Eley@sonopath.com