



PATIENT

Quatro Martens

PRESENTING CLINICAL SIGNS

Quatro is a 13-year-old neutered male Russian Blue cat, has a history of hyporexia and lethargy over the last few days. Upon abdominal palpation, a big mass was palpated on his cranial abdomen.

SPECIES

Feline

RADIOGRAPHIC STUDY OF THE ABDOMEN

Right/left lateral and ventrodorsal views of the abdomen totaling 4 images available for review.

BREED

Russian Blue

RADIOGRAPHIC FINDINGS

An 8.5 cm sized soft tissue opaque ill-defined mass is seen in the cranioventral abdomen caudal to the stomach and ventral to the splenic head. The colon is pushed caudally. The small intestine is pushed caudally as well as ventrally. The lesion margins are ill-defined with regionally decreased serosal detail and presence of free peritoneal gas. Mineral opaque foci within the free mesentery appears to be present.

SEX

Neutered Male

RADIOGRAPHIC DIAGNOSIS

- Large cranioventral abdomen soft tissue mass with reduced serosal detail and suspect pneumoperitoneum as well as suspect hollow viscus leakage.

AGE

13 Years

INTERPRETATION OF THE FINDINGS & FURTHER RECOMMENDATIONS

The radiographic findings do not only suggest presence of a large cranioventral abdominal mass. There also is indication of pneumoperitoneum, peritonitis, and the potential for leakage from the gastrointestinal tract. Intestinal tract and mesentery including the mesenteric lymph nodes are thought the most likely organs of origin based on the position and deviation of the remainder of the abdominal tissues. The findings strongly suggest involvement of the gastrointestinal tract with septic peritonitis and wall breakdown. Consider further definition by means of abdominal ultrasound and if this is not available, direct surgical exploration should be considered.

INTERPRETED BY

Nele Eley, DVM
Dr. med. Vet. DipECVDI

HOSPITAL NAME

Beaches-Fallingbrook
Veterinary Clinic

REFERRING VET

Dr Sam Shahsavari

INVOICE

54323

DATE

9-27-22



PATIENT

Quatro Martens

SPECIES

Feline

BREED

Russian Blue

SEX

Neutered Male

AGE

13 Years

INTERPRETED BY

Nele Eley, DVM
Dr. med. Vet. DipECVDI

HOSPITAL NAME

Beaches-Fallingbrook
Veterinary Clinic

REFERRING VET

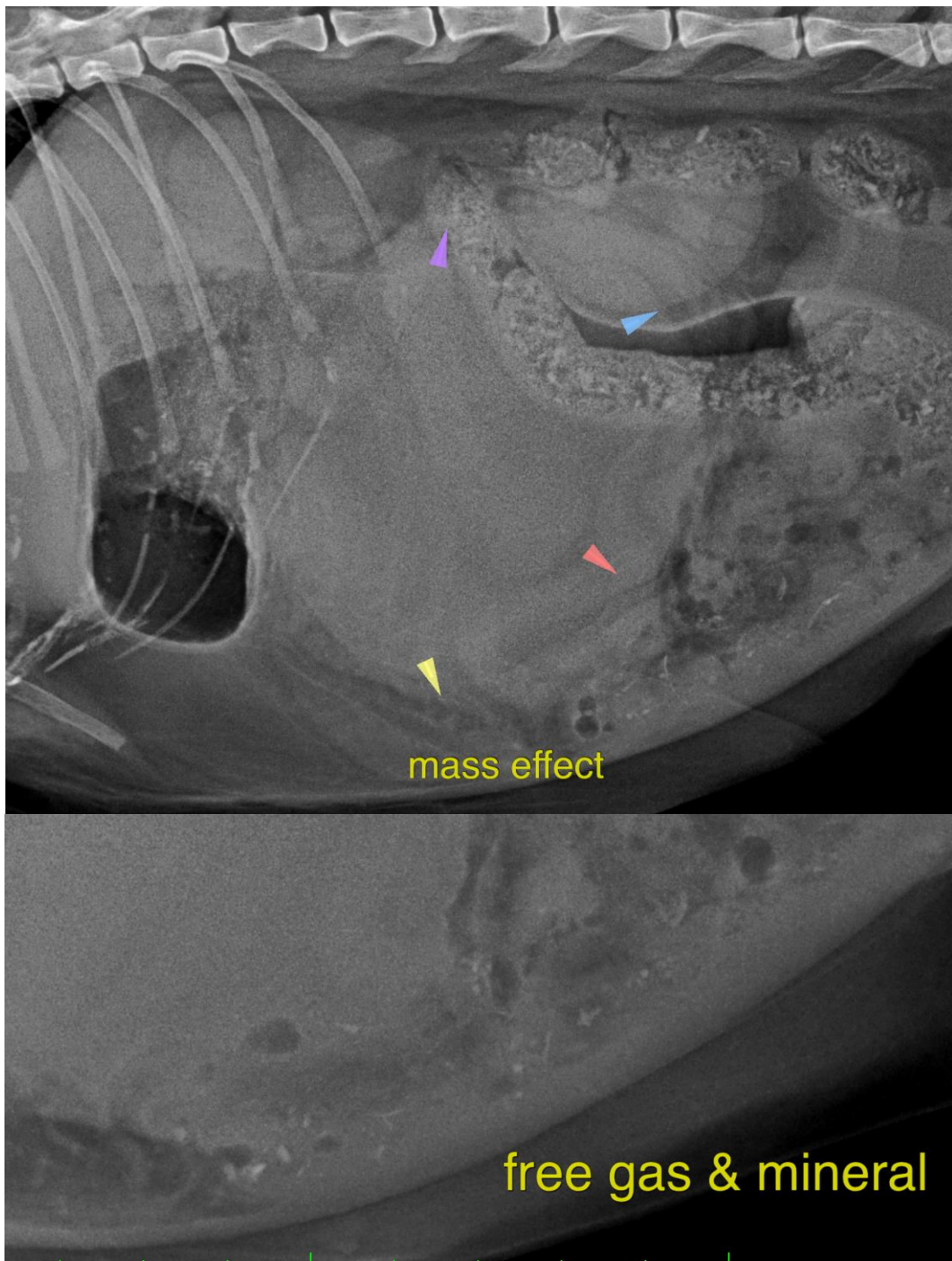
Dr Sam Shavsavari

INVOICE

54323

DATE

9-27-22





PATIENT

Quatro Martens

The information and recommendations provided are based on the images presented by the referring veterinarian/sonographer. No evaluation can be communicated regarding pathology that was not visible in the image/video clips provided.

SPECIES

Feline

Thank you for this referral. If the clinical or image interpretation does not parallel your findings or if I can be of any further assistance please contact me.

BREED

Russian Blue

Nele Eley, DVM, Dr. med. vet., DipECVDI
European Specialist in Veterinary Diagnostic Imaging, Cert. Radiology,
Senior lecturer University of Giessen, Germany, Veterinary Faculty, Department of Radiology
Nele.Eley@sonopath.com

SEX

Neutered Male

AGE

13 Years

INTERPRETED BY

Nele Eley, DVM
Dr. med. Vet. DipECVDI

HOSPITAL NAME

Beaches-Fallingbrook
Veterinary Clinic

REFERRING VET

Dr Sam Shavsavari

INVOICE

54323

DATE

9-27-22