



PATIENT

Lucy Disney

PRESENTING CLINICAL SIGNS

P was seen 9/6/22 for limping on the right front limb. CT was performed on this day and repeated bc elbows were not in the CT scan

SPECIES

Canine

COMPUTED TOMOGRAPHIC STUDY OF THE RIGHT ELBOW

Plain and post contrast studies available for review.

BREED

Beagle Mix

COMPUTED TOMOGRAPHIC FINDINGS

Blurred outline and decreased opacity of the right medial coronoid process are noted. There is a fissure line within the medial coronoid process within the radioulnar incisure, which appears to isolate a small semicircular shaped fragment. Smooth periarticular new bone formation is noted. The subchondral bone of the medial humeral condyle is intact.

SEX

SF

COMPUTED TOMOGRAPHIC DIAGNOSIS

- Medial coronoid pathology of the right elbow with mild secondary osteoarthritis.

AGE

7 Years

INTERPRETATION OF THE FINDINGS & FURTHER RECOMMENDATIONS

The radiographic findings support the presence of medial coronoid pathology with fragmentation within the right elbow as well as secondary degenerative joint disease. Depending on the size of the patient and depending on the severity of the clinical signs, arthroscopic revision of the right elbow should be considered.

INTERPRETED BY

Nele Eley, DVM
Dr. med. Vet. DipECVDI

HOSPITAL NAME

Petroglyph Animal
Hospital

REFERRING VET

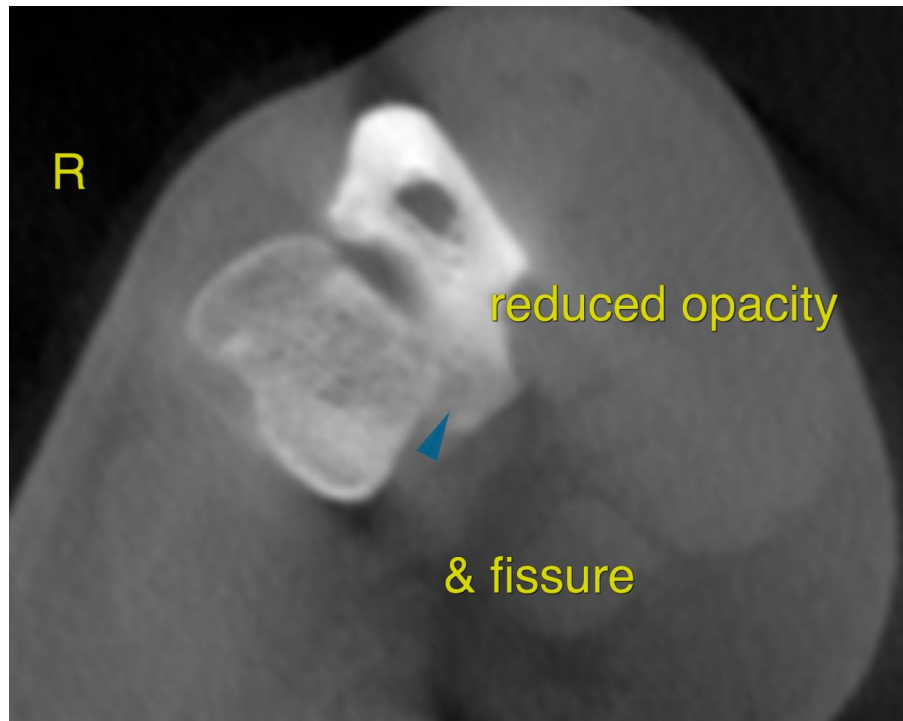
Dr. Raymond Hudgell

INVOICE

54337

DATE

9-27-22





PATIENT

Lucy Disney

The information and recommendations provided are based on the images presented by the referring veterinarian/sonographer. No evaluation can be communicated regarding pathology that was not visible in the image/video clips provided.

SPECIES

Canine

Thank you for this referral. If the clinical or image interpretation does not parallel your findings or if I can be of any further assistance please contact me.

BREED

Beagle Mix

Nele Eley, DVM, Dr. med. vet., DipECVDI
European Specialist in Veterinary Diagnostic Imaging, Cert. Radiology,
Senior lecturer University of Giessen, Germany, Veterinary Faculty, Department of Radiology
Nele.Eley@sonopath.com

SEX

SF

AGE

7 Years

INTERPRETED BY

Nele Eley, DVM
Dr. med. Vet. DipECVDI

HOSPITAL NAME

Petroglyph Animal
Hospital

REFERRING VET

Dr. Raymond Hudgell

INVOICE

54337

DATE

9-27-22