



PATIENT

Ames Zimmerman

SPECIES

Feline

BREED

DSH

SEX

Female Spayed

AGE

1 Year

INTERPRETED BY

Nele Eley, DVM
Dr. med. Vet. DipECVDI

HOSPITAL NAME

Northvale Veterinary
Clinic

REFERRING VET

Dr. Stefanie Simon

INVOICE

54322

DATE

9-27-22

PRESENTING CLINICAL SIGNS

POSSIBLY urinating outside litter box and possible hematuria noted. No PU/PD or stranguria noted. E/D/D fine and no V/D/C/S. BAR, active and no lethargy noted.
Abnormal PE/Chem/CBC/UA Results: WBC 4.7 with mild neutropenia, USG 1.054. pH 5.5, 2+ proteinuria, 3+ hematuria, 2-5 WBC, 50-75 RBC, 2+ epi cells, no crystalluria, no bacteruria, all else WNL.

RADIOGRAPHIC STUDY OF THE ABDOMEN

Right/left lateral and ventrodorsal views of the abdomen totaling 3 images available for review.

RADIOGRAPHIC FINDINGS

The urinary bladder is moderately distended. Faintly mineral opaque material appears to superimpose with the urinary bladder in the lateral views. There is no evidence of urinary calculi level with the kidneys or ureters.

The liver, kidneys, and gastrointestinal tract present within normal limits.

RADIOGRAPHIC DIAGNOSIS

- Possible urinary bladder microlithiasis.

INTERPRETATION OF THE FINDINGS & FURTHER RECOMMENDATIONS

The radiographic findings suggest potential for presence of urinary bladder calculi/sand. The possibility of feline lower urinary tract disease should be considered and further definition by means of full urinalysis and abdominal ultrasound could be considered.



PATIENT

Ames Zimmerman

SPECIES

Feline

BREED

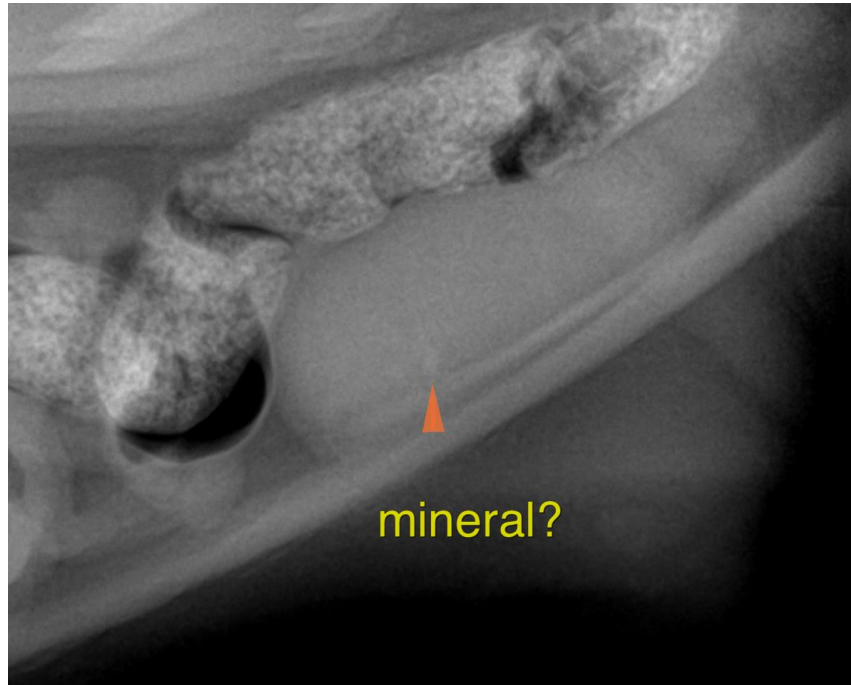
DSH

SEX

Female Spayed

AGE

1 Year



INTERPRETED BY

Nele Eley, DVM
Dr. med. Vet. DipECVDI

The information and recommendations provided are based on the images presented by the referring veterinarian/sonographer. No evaluation can be communicated regarding pathology that was not visible in the image/video clips provided.

Thank you for this referral. If the clinical or image interpretation does not parallel your findings or if I can be of any further assistance please contact me.

HOSPITAL NAME

Northvale Veterinary
Clinic

Nele Eley, DVM, Dr. med. vet., DipECVDI
European Specialist in Veterinary Diagnostic Imaging, Cert. Radiology,
Senior lecturer University of Giessen, Germany, Veterinary Faculty, Department of Radiology
Nele.Eley@sonopath.com

REFERRING VET

Dr. Stefanie Simon

INVOICE

54322

DATE

9-27-22