



PATIENT

Alika Speier

PRESENTING CLINICAL SIGNS

1 week history of acute onset sneezing, mild mucoid discharge from L nostril progressing to mild L-sided epistaxis.

SPECIES

Canine

Abnormal PE/Chem/CBC/UA Results: Mild mucoid discharge and epistaxis L nare. Chem WNL. Evaluation under anesthesia revealed mild volume mucopurulent nasal discharge, no masses/foreign material visualized with otoscope attachment.

BREED

Chihuahua Mix

COMPUTED TOMOGRAPHIC STUDY OF THE HEAD

Plain and post contrast studies available for review.

SEX

MN

COMPUTED TOMOGRAPHIC FINDINGS

Dental-nasal fistulae with partial loss of the lamina dura are seen associated with the triadans 104, 105, 204, and 205.

AGE

14 Years

Within the rostral aspect of both nasal cavities, there is regional turbinate destruction, mucosal swelling, and fluid accumulation. The changes are symmetric between the right and left nasal cavity. The remainder of the nasal cavities and frontal sinuses present within normal limits.

Mild widening of the periodontium is seen associated with the triadans 109, 209, and 410.

The right and left submandibular lymph nodes are mildly enlarged.

INTERPRETED BY

Nele Eley, DVM
Dr. med. Vet. DipECVDI

COMPUTED TOMOGRAPHIC DIAGNOSIS

- Bilateral dental-nasal fistula due to severe periodontitis of the triadans 104, 105, 204, and 205 with regionally destructive rhinitis.
- Periodontal disease triadans 109, 209, and 410.
- Mild bilateral submandibular lymphadenomegaly.

HOSPITAL NAME

Healing Spirit Animal
Wellness

INTERPRETATION OF THE FINDINGS & FURTHER RECOMMENDATIONS

The CT study reveals regionally destructive rhinitis in the rostral aspect of both nasal cavities secondary to dental-nasal fistulae formation of the triadans 104, 105, 204, and 205.

REFERRING VET

Desen Ertunc

The lymph node changes are compatible with reactive lymphadenitis.

Consider dental revisions and extractions as well as revision of the dental-nasal fistulae.

INVOICE

54319

DATE

9-27-22



PATIENT

Alika Speier

SPECIES

Canine

BREED

Chihuahua Mix

SEX

MN

AGE

14 Years

INTERPRETED BY

Nele Eley, DVM
Dr. med. Vet. DipECVDI

HOSPITAL NAME

Healing Spirit Animal
Wellness

REFERRING VET

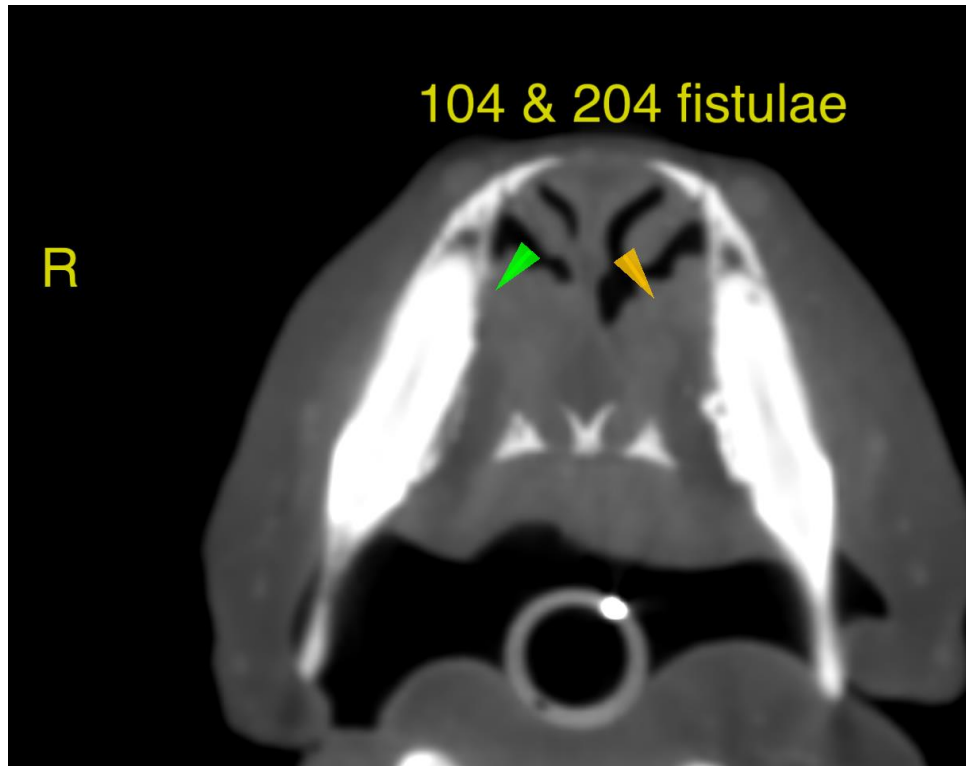
Desen Ertunc

INVOICE

54319

DATE

9-27-22



The information and recommendations provided are based on the images presented by the referring veterinarian/sonographer. No evaluation can be communicated regarding pathology that was not visible in the image/video clips provided.

Thank you for this referral. If the clinical or image interpretation does not parallel your findings or if I can be of any further assistance please contact me.

Nele Eley, DVM, Dr. med. vet., DipECVDI
European Specialist in Veterinary Diagnostic Imaging, Cert. Radiology,
Senior lecturer University of Giessen, Germany, Veterinary Faculty, Department of Radiology
Nele.Eley@sonopath.com