



**PATIENT**

Sunshine Lobland

**PRESENTING CLINICAL SIGNS**

P has a long-standing history of persistent cough and/or sneeze that has been attributed to allergies. Antihistamine medication has worked well in the past but has become less effective recently.

**SPECIES**

Canine

Abnormal PE/Chem/CBC/UA Results: Tracheal palpation elicits a dry, mild cough Wheezes auscultated on thoracic evaluation (no crackles or pops noted) Bilateral MLPs

**BREED**

Maltese Mix

**RADIOGRAPHIC STUDY OF THE THORAX**

Right/left lateral and ventrodorsal views totaling 3 images available for review.

**RADIOGRAPHIC FINDINGS**

The patient is obese.

**SEX**

MN

The degree of pulmonary inflation is fair. A moderate generalized bronchointerstitial lung pattern is seen with even distribution throughout the lung.

Moderate to severe cervical tracheal collapse is noted on both lateral views.

**AGE**

8

No evidence of cardiovascular pathology is noted. The vertebral heart score is 9.5.

The mediastinum presents within the expected limits.

**INTERPRETED BY**

Nele Eley, DVM  
Dr. med. Vet. DipECVDI

There is moderate gastric aerophagia in a post-prandial stomach.

**RADIOGRAPHIC DIAGNOSIS**

- Moderate to severe tracheal collapse.
- Moderate generalized bronchointerstitial lung pattern.
- Aerophagia.
- Obesity.

**HOSPITAL NAME**

Boca Park Animal  
Hospital

**INTERPRETATION OF THE FINDINGS & FURTHER RECOMMENDATIONS**

Moderate to severe cervical tracheal collapse is noted which appears to correlate well with the clinical history of the patient.

**REFERRING VET**

Tifanie Silver

The lung findings are compatible with the history of presumed allergic lower airway disease as well. Eosinophilic bronchopneumopathy is one major differential diagnosis for the pertinent radiographic findings. Infectious bronchitis such as viral, bacterial, parasitic, or protozoal is a theoretical potential as well.

**INVOICE**

47567

Upper and lower airway endoscopy could be considered for further definition. Consider weight management.

**DATE**

9-27-21



**PATIENT**

Sunshine Lobland

**SPECIES**

Canine

**BREED**

Maltese Mix

**SEX**

MN

**AGE**

8

**INTERPRETED BY**

Nele Eley, DVM  
Dr. med. Vet. DipECVDI

**HOSPITAL NAME**

Boca Park Animal  
Hospital

**REFERRING VET**

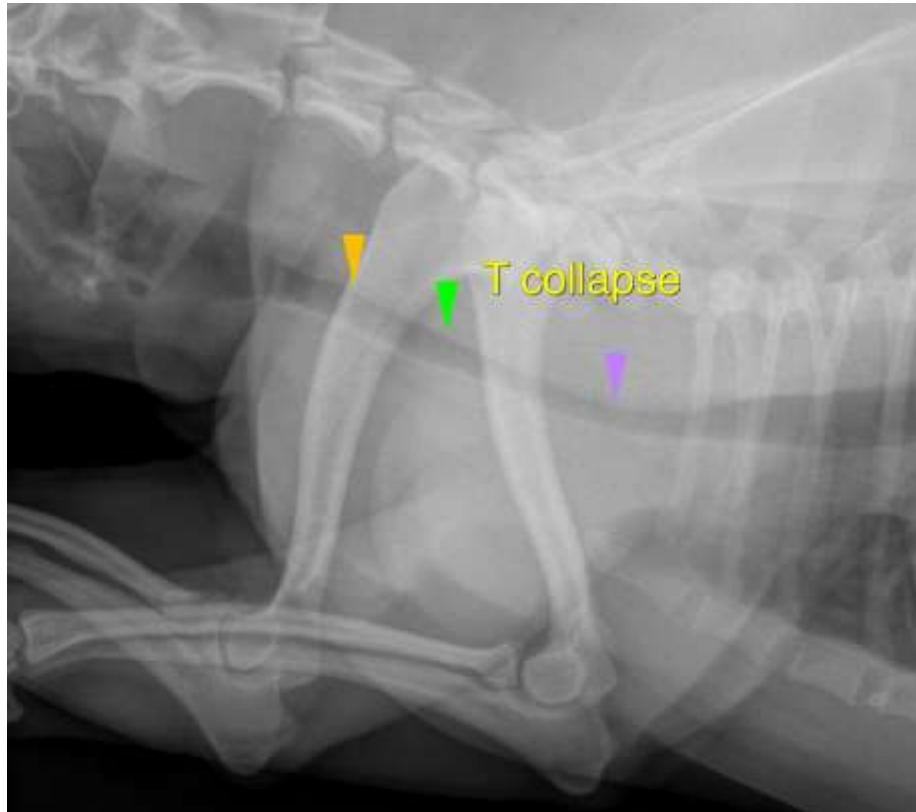
Tifanie Silver

**INVOICE**

47567

**DATE**

9-27-21



The information and recommendations provided are based on the images presented by the referring veterinarian. No evaluation can be communicated regarding pathology that was not visible in the image/video clips provided.

Thank you for this referral. If the clinical or image interpretation does not parallel your findings or if I can be of any further assistance please contact me.

**Nele Eley**, DVM, Dr. med. vet., DipECVDI  
European Specialist in Veterinary Diagnostic Imaging, Cert. Radiology,  
Senior lecturer University of Giessen, Germany, Veterinary Faculty, Department of Radiology  
Nele.Eley@sonopath.com