

**PATIENT**

Ava Frawley

PRESENTING CLINICAL SIGNS

Acute lameness on left rear leg after jumping off bed the previous night. On P.E. Non wt bearing lameness of left rear leg, instability of left stifle, No pain elicited on palpation of limbs or reduced range of motion

SPECIES

Canine

RADIOGRAPHIC STUDY OF THE STIFLES

Mediolateral and craniocaudal views of both stifles totaling 3 images available for review.

BREED

Beagle Mix

RADIOGRAPHIC FINDINGS

The long bones are stunted with prominent bony protuberances which is typical in chondrodystrophic dogs.

SEX

SF

Severe articular swelling of the left stifle joint appears to be present. A moderate amount of periarticular osteophytes is seen in the femoral trochlear, distal pole of the patellar, and cranial margin of the tibial plateau. There appears to be mild cranial subluxation of the tibia with respect to the femoral condyles.

AGE

8

There is mild articular swelling of the right stifle joint. A mild amount of periarticular osteophytes is seen in the femoral trochlear and distal pole of the patellar.

The patella present in situ in both stifles.

INTERPRETED BY

Nele Eley, DVM
Dr. med. Vet. DipECVDI

RADIOGRAPHIC DIAGNOSIS

- Bilateral stifle arthropathy with severe articular swelling and moderate osteoarthritic changes of the left and mild articular swelling and mild osteoarthritic changes of the right stifle.

HOSPITAL NAME

Paws and Claws
Urgent Care

INTERPRETATION OF THE FINDINGS & FURTHER RECOMMENDATIONS

The radiographic findings are compatible with the history of cranial cruciate ligament injury as indicated per the instability of the left stifle joint. Moderate osteoarthritic changes with marked articular swelling of the left stifle are seen. There appears to be mild cranial thrust of the tibia. The right stifle presents similar changes which are less pronounced at this point.

REFERRING VET

Dr. Juarez

INVOICE

47560

DATE

9-27-21



PATIENT

Ava Frawley

SPECIES

Canine

BREED

Beagle Mix

SEX

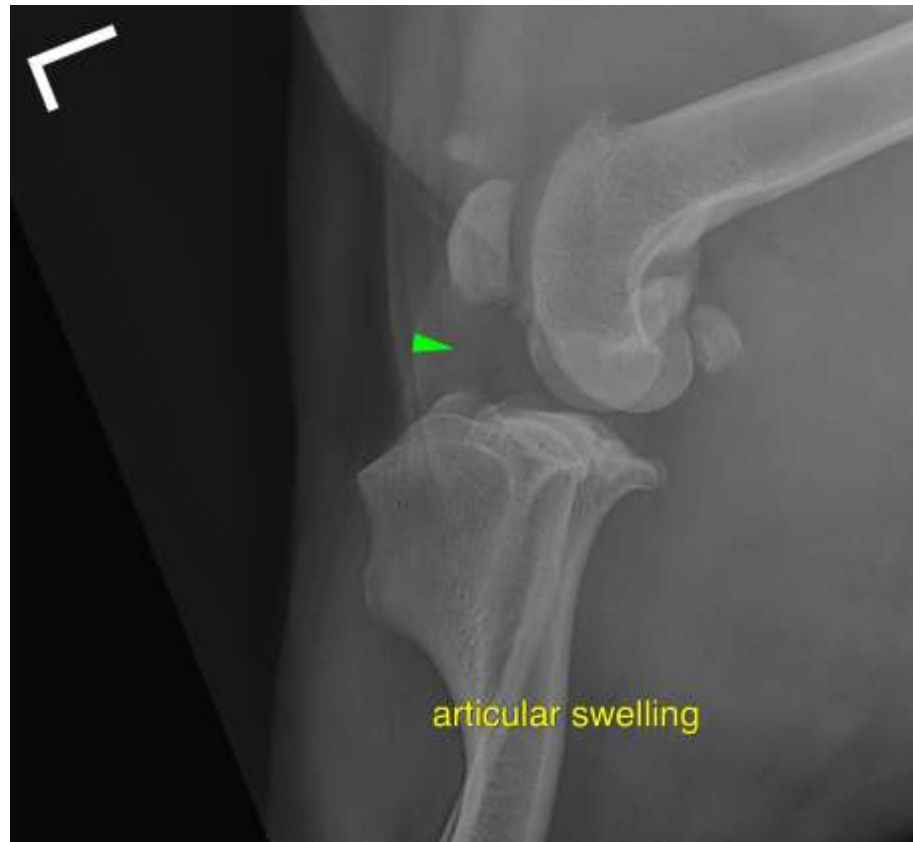
SF

AGE

8

INTERPRETED BY

Nele Eley, DVM
Dr. med. Vet. DipECVDI



HOSPITAL NAME

Paws and Claws
Urgent Care

REFERRING VET

Dr. Juarez

INVOICE

47560

DATE

9-27-21

The information and recommendations provided are based on the images presented by the referring veterinarian. No evaluation can be communicated regarding pathology that was not visible in the image/video clips provided.

Thank you for this referral. If the clinical or image interpretation does not parallel your findings or if I can be of any further assistance please contact me.

Nele Eley, DVM, Dr. med. vet., DipECVDI
European Specialist in Veterinary Diagnostic Imaging, Cert. Radiology,
Senior lecturer University of Giessen, Germany, Veterinary Faculty, Department of Radiology
Nele.Eley@sonopath.com