



PATIENT PRESENTING CLINICAL SIGNS

Max Walder Intermittent Front Leg Lameness; Varies from Weight bearing to Non-Weight bearing 3 Legged Lameness. Chronic Hx of Skin allergies; On Heska Allergy Serum; Prior Hx of Apoqual Usage. Marked Red Raised inter-digital Pyoderma with Purulent Discharge noted from interdigital Spaces.

SPECIES Abnormal PE/Chem/CBC/UA Results: Superchemistry: Pending CBC: Pending T4: Pending
Canine Accuplex: Pending

BREED Radiographic Study of the Elbows
Mix Mediolateral views of the left and right elbows available for review.

SEX Radiographic Findings
Male Neutered The right elbow presents within normal limits. The medial coronoid process is well delineated and uniform in opacity. The joint spaces are congruent. There is no evidence of subchondral bone defects or osteophytes.

AGE Radiographic Findings
3 Years, 2 Months The medial coronoid process of the left elbow is well delineated and uniform in opacity. However, there appears to be mild sclerosis, subtrochlear notch of the ulnar, and a mild amount of smooth new bone on the proximal contour of the anconeal process.

INTERPRETED BY Radiographic Diagnosis
Nele Eley, DVM
Dr. med. Vet. DipECVDI

- Radiographic evidence of minimal degenerative joint disease of the left elbow.
- Radiographically normal right elbow.

HOSPITAL NAME Interpretation of the Findings & Further Recommendations
Summit Dog & Cat Hospital

The significance of the minimal radiographic changes in the left elbow is uncertain. There is a small fraction of patients with medial coronoid pathology with negative radiographic findings on radiographs. This fraction is about 1-2% and it is more likely that the minimal radiographic changes are not the cause of the lameness. However, in case of definitive clinical signs of pain and lameness from the left elbow, further definition by means of CT could be considered.

REFERRING VET
Vogler

INVOICE
54295

DATE
9-26-22



PATIENT

Max Walder

SPECIES

Canine

BREED

Mix

SEX

Male Neutered

AGE

3 Years, 2 Months

INTERPRETED BY

Nele Eley, DVM
Dr. med. Vet. DipECVDI

HOSPITAL NAME

Summit Dog & Cat
Hospital

REFERRING VET

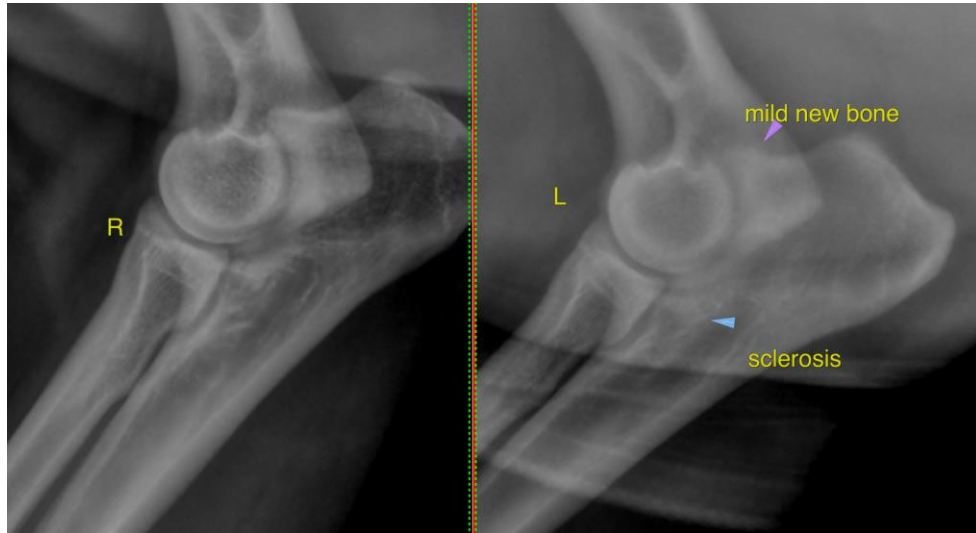
Vogler

INVOICE

54295

DATE

9-26-22



The information and recommendations provided are based on the images presented by the referring veterinarian/sonographer. No evaluation can be communicated regarding pathology that was not visible in the image/video clips provided.

Thank you for this referral. If the clinical or image interpretation does not parallel your findings or if I can be of any further assistance please contact me.

Nele Eley, DVM, Dr. med. vet., DipECVDI
European Specialist in Veterinary Diagnostic Imaging, Cert. Radiology,
Senior lecturer University of Giessen, Germany, Veterinary Faculty, Department of Radiology
Nele.Eley@sonopath.com