



**PATIENT**

Kiki Sinatra

**PRESENTING CLINICAL SIGNS**

P began coughing 3 days ago. O has a doggy daycare/grooming facility. Seems lethargic. Coughed a few times in room. Auscultation nosf.

**SPECIES**

Canine

**RADIOGRAPHIC STUDY OF THE THORAX**

Right/left lateral and ventrodorsal views of the thorax totaling 3 images available for review.

**BREED**

Dalmatian

**RADIOGRAPHIC FINDINGS**

The degree of pulmonary inflation is moderate. A moderate generalized bronchointerstitial lung pattern with mild caudodorsal accentuation is seen.

**SEX**

SF

The radiographic presentation of the cardiac silhouette is within normal limits. The vertebral heart score is 9.5. The reference range is up to 10.5.

There is esophageal aerophagia with a tracheal stripe sign and gastric aerophagia.

**AGE**

9 Months

No evidence of mediastinal lymphadenomegaly is seen. A thymic remnant is seen and considered within normal age related limits.

**RADIOGRAPHIC DIAGNOSIS**

- Moderate bronchointerstitial lung pattern with caudodorsal accentuation.
- Aerophagia – likely due to respiratory distress.
- Thymic remnant – normal age related finding.
- No radiographic evidence of cardiovascular pathology.

**INTERPRETED BY**

Nele Eley, DVM  
Dr. med. Vet. DipECVDI

**INTERPRETATION OF THE FINDINGS & FURTHER RECOMMENDATIONS**

The radiographic findings suggest potential for bronchopneumopathy. Canine infectious respiratory disease complex is one primary differential diagnosis and would fit the radiographic findings. However, other infectious and allergic bronchopneumopathy cannot be ruled out as differential diagnoses. Consider a clinical trial of treatment for bronchopneumonia versus further definition by means of airway sampling. Proactive deworming could be considered if not performed already.

**HOSPITAL NAME**

The Pet Hospital of  
Stratford

**REFERRING VET**

Dr. Claudia Giuliani

**INVOICE**

54297

**DATE**

9-26-22



**PATIENT**

Kiki Sinatra

**SPECIES**

Canine

**BREED**

Dalmatian

**SEX**

SF

**AGE**

9 Months

**INTERPRETED BY**

Nele Eley, DVM  
Dr. med. Vet. DipECVDI

**HOSPITAL NAME**

The Pet Hospital of  
Stratford

**REFERRING VET**

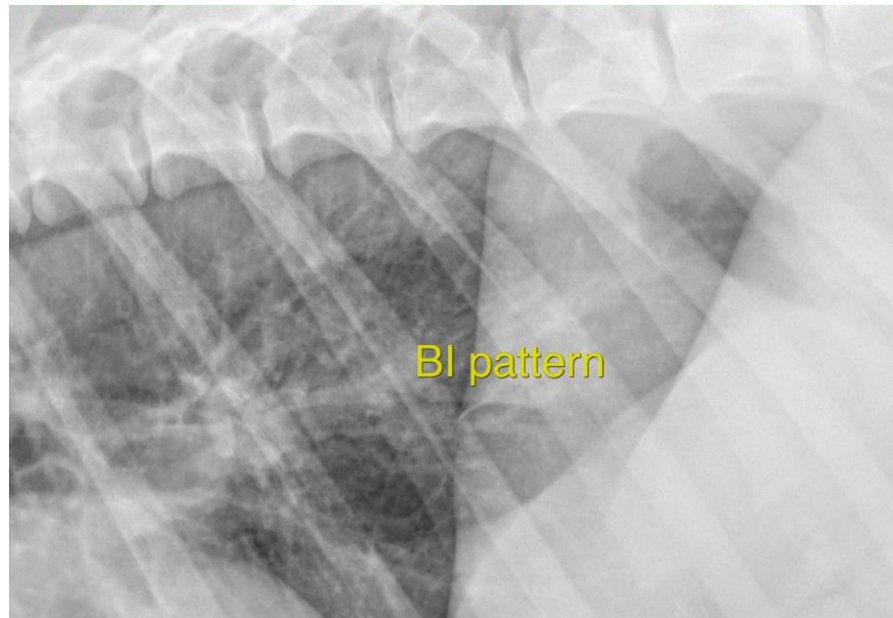
Dr. Claudia Giuliani

**INVOICE**

54297

**DATE**

9-26-22



The information and recommendations provided are based on the images presented by the referring veterinarian/sonographer. No evaluation can be communicated regarding pathology that was not visible in the image/video clips provided.

Thank you for this referral. If the clinical or image interpretation does not parallel your findings or if I can be of any further assistance please contact me.

**Nele Eley**, DVM, Dr. med. vet., DipECVDI  
European Specialist in Veterinary Diagnostic Imaging, Cert. Radiology,  
Senior lecturer University of Giessen, Germany, Veterinary Faculty, Department of Radiology  
Nele.Eley@sonopath.com