



**PATIENT PRESENTING CLINICAL SIGNS**

Jones Bondy referred from another animal hospital for biopsy and dental x-ray ,had tooth abscess since last July , 107, 108 were extracted swelling of the face did not change , and not responding to the Abs., samples sent for path.

**SPECIES** Abnormal PE/Chem/CBC/UA Results: sever swelling of the right of the face , eye discharge from the right eye , BW WNL , xray sent to check for bone lysis at the right side of the skull.

Feline

**RADIOGRAPHIC STUDY OF THE HEAD**

**BREED** Multiple whole body views including the head are available for review.

DSH

**RADIOGRAPHIC FINDINGS**

There is increased soft tissue opacity in the facial cranium to the right of the midline in combination with obscured delineation of the nasal turbinates and conchae and reduced delineation of the outline of the right frontal bone, caudal margin of the zygomatic arch, and right bony orbita.

**SEX**

Female Spayed

Multiple teeth are absent, especially in the maxillary molar areas.

**AGE**

12

**RADIOGRAPHIC DIAGNOSIS**

- Suspect conchae and bone lysis in the right nasal cavity, right orbita, and right frontal bone.

**INTERPRETED BY**

Nele Eley, DVM  
Dr. med. Vet. DipECVDI

**INTERPRETATION OF THE FINDINGS & FURTHER RECOMMENDATIONS**

Definitive aggressive osteolytic changes in the periphery of the osseous limits of the nasal cavities and frontal sinuses cannot be identified, yet the findings suggest presence of turbinate and conchae lysis as well as early bone lysis in the region of the right frontal bone, right bony orbita, and nasal cavity, prioritizing aggressive bone disease including neoplasia and erosive rhinitis among other differential diagnoses such as nonerosive rhinitis.

**HOSPITAL NAME**

Lakeshore Woods  
Animal Hospital

**REFERRING VET**

Dr. Sam Masoud

**INVOICE**

54288

**DATE**

9-26-22



**PATIENT**

Jones Bondy

**SPECIES**

Feline

**BREED**

DSH

**SEX**

Female Spayed

**AGE**

12

**INTERPRETED BY**

Nele Eley, DVM  
Dr. med. Vet. DipECVDI

**HOSPITAL NAME**

Lakeshore Woods  
Animal Hospital

**REFERRING VET**

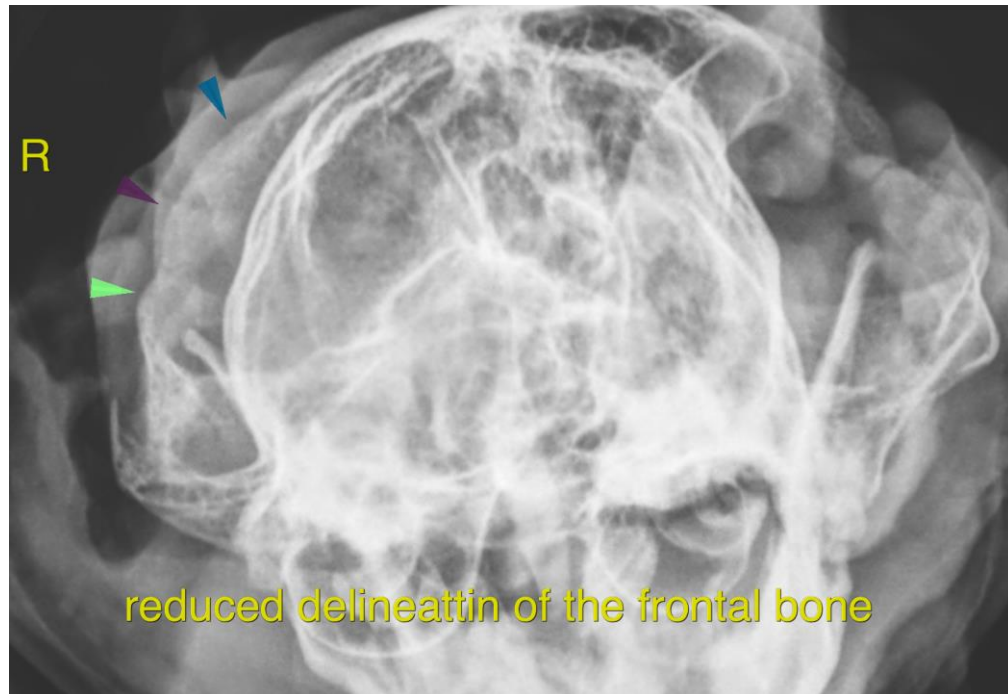
Dr. Sam Masoud

**INVOICE**

54288

**DATE**

9-26-22



The information and recommendations provided are based on the images presented by the referring veterinarian/sonographer. No evaluation can be communicated regarding pathology that was not visible in the image/video clips provided.

Thank you for this referral. If the clinical or image interpretation does not parallel your findings or if I can be of any further assistance please contact me.

**Nele Eley**, DVM, Dr. med. vet., DipECVDI  
European Specialist in Veterinary Diagnostic Imaging, Cert. Radiology,  
Senior lecturer University of Giessen, Germany, Veterinary Faculty, Department of Radiology  
Nele.Eley@sonopath.com