



PATIENT

Dora Gueslin

PRESENTING CLINICAL SIGNS

HEARTWORM POSITIVE

SPECIES

Canine

RADIOGRAPHIC STUDY OF THE THORAX

Right/left lateral and ventrodorsal views of the thorax totaling 3 images available for review.

BREED

American
Staffordshire

RADIOGRAPHIC FINDINGS

The surrounding bony structures are within normal limits.

SEX

Female

The extrathoracic soft tissues present homogeneous without abnormalities.

The vertebral heart score is 10.5. Rounding of the right ventricle with increased sternal contact is seen. Enlargement of the main pulmonary artery is noted. The lobar pulmonary arteries are tortuous and appear to be engorged. A generalized vascular lung pattern is noted as well as multifocal bronchoalveolar infiltrates which are caudodorsally accentuated. No broadening of the caudal vena cava is seen.

AGE

2 Years, 6 Months

The cranial mediastinum presents the expected soft tissue opacity. The mediastinal width is less than twice the width of the vertebral column at the same level.

The trachea is normal in diameter and presents the anticipated course. The luminal outline of the trachea is smooth.

INTERPRETED BY

Nele Eley, DVM
Dr. med. Vet. DipECVDI

The diaphragm is well delineated with even surface and the expected mild cranial bulging of the diaphragmatic cupola.

RADIOGRAPHIC DIAGNOSIS

- Bronchoalveolar lung pattern with caudodorsal accentuation.
- Mild right sided cardiomegaly with main pulmonary artery enlargement – compatible with cor pulmonale.

HOSPITAL NAME

DPC Veterinary
Hospital

INTERPRETATION OF THE FINDINGS & FURTHER RECOMMENDATIONS

The radiographic findings are consistent with the history of heartworm infection. The caudodorsally accentuated bronchoalveolar lung pattern, the vascular lung pattern, and right sided cardiomegaly would fit a radiographic heartworm presentation. The radiographic signs are known to semi quantitatively correlate with the degree of worm burden and active infection should be considered likely based on the radiographic findings. Further testing and treatment according to the guidelines of the American Heartworm Society could be considered if not performed already. Other differential diagnoses such as lungworm infection, bacterial, or viral bronchopneumonia are theoretical but less likely differential diagnoses.

REFERRING VET

Dr. Rivera

INVOICE

54287

DATE

9-26-22



PATIENT

Dora Gueslin

SPECIES

Canine

BREED

American
Staffordshire

SEX

Female

AGE

2 Years, 6 Months

INTERPRETED BY

Nele Eley, DVM
Dr. med. Vet. DipECVDI

HOSPITAL NAME

DPC Veterinary
Hospital

REFERRING VET

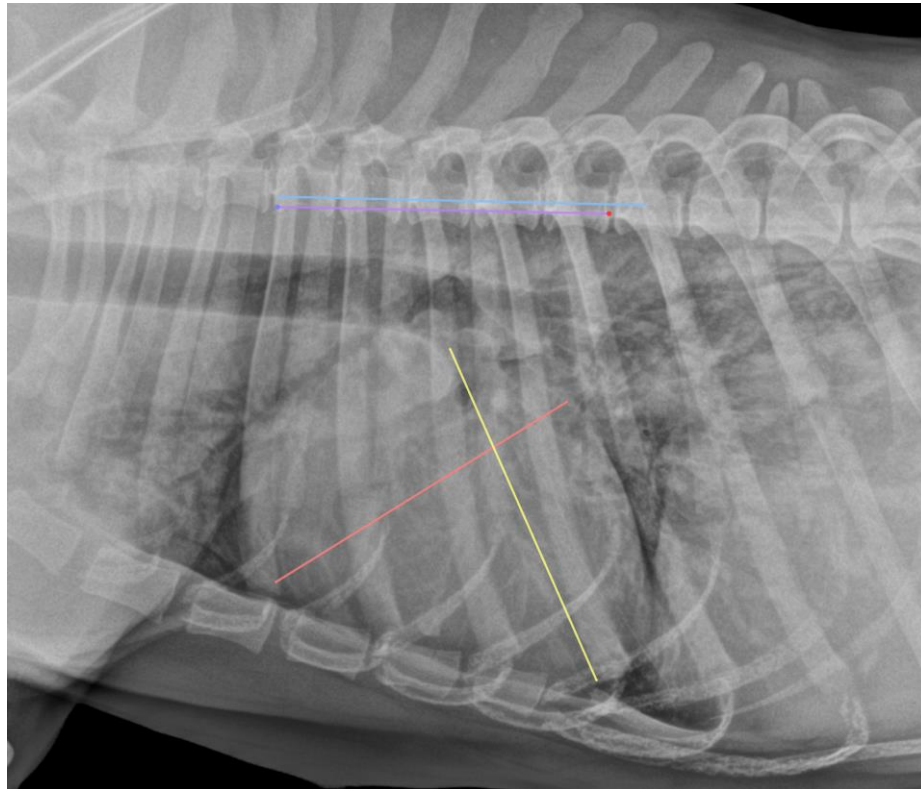
Dr. Rivera

INVOICE

54287

DATE

9-26-22



The information and recommendations provided are based on the images presented by the referring veterinarian/sonographer. No evaluation can be communicated regarding pathology that was not visible in the image/video clips provided.

Thank you for this referral. If the clinical or image interpretation does not parallel your findings or if I can be of any further assistance please contact me.

Nele Eley, DVM, Dr. med. vet., DipECVDI
European Specialist in Veterinary Diagnostic Imaging, Cert. Radiology,
Senior lecturer University of Giessen, Germany, Veterinary Faculty, Department of Radiology
Nele.Eley@sonopath.com