



PATIENT

Jedi Rook

PRESENTING CLINICAL SIGNS

Presented for lethargy, vomiting daily, elevated liver enzymes:
Abnormal PE/Chem/CBC/UA Results: Elevated alt/alp/ask/t.bili

SPECIES

Canine

COMPUTED TOMOGRAPHIC STUDY OF THE THORAX & ABDOMEN

Plain and post contrast studies of the abdomen and post contrast study only of the thorax available for review.

BREED

Labrador Retriever

COMPUTED TOMOGRAPHIC FINDINGS

Abdomen

Reduced serosal detail with peritoneal fat stranding is seen accentuating the cranial abdomen.

SEX

MN

There appear to be two populations of small bowel with one mildly dilated segment concentrated in the right cranial and ventral abdomen. The nondilated loops are empty and present mild generalized wall thickening with maintained layering.

AGE

5

There is mild to moderate multifocal regional mesenteric lymphadenomegaly.

Mild diffuse enlargement of the pancreas is seen.

INTERPRETED BY

Nele Eley, DVM
Dr. med. Vet. DipECVDF

Thorax

The bony and surrounding soft tissue structures are within normal limits.

Moderate enlargement of one sternal lymph node is noted. The cranial mediastinal and tracheobronchial lymph nodes present within normal limits.

HOSPITAL NAME

Northeast Veterinary
Referral Hospital

The cardiovascular structures including the pulmonary vasculature are within normal limits.

The bronchial tree presents with regular branching and tapers uniformly towards the periphery as expected, the bronchial walls are thin and smooth. The bronchus-to-artery ratio is within normal limits.

REFERRING VET

Dr. Runde

The lung parenchyma presents the expected architecture and attenuation behavior.

Small incidental gas pockets are seen within the esophageal lumen, there is no evidence of abnormal dilation.

INVOICE

47521

COMPUTED TOMOGRAPHIC DIAGNOSIS

- Suspect mechanical small intestinal ileus with peritonitis.
- Pancreatopathy
- Mesenteric lymphadenomegaly.
- Sternal lymphadenomegaly.

DATE

9-24-21



PATIENT

Jedi Rook

INTERPRETATION OF THE FINDINGS & FURTHER RECOMMENDATIONS

The CT findings are highly suggestive for mechanical ileus / subileus. Functional ileus is thought less likely based on the CT findings. The exact cause of the ileus cannot be delineated; however, there appears to be regional peritonitis as well as mesenteric lymphadenopathy.

SPECIES

Canine

The diffuse swelling of the pancreas may be due to edema or pancreatitis.

BREED

Labrador Retriever

The lymphadenomegaly may represent reactive lymphadenitis. Infiltrative pathology cannot be ruled out entirely.

The enlargement of the sternal lymph node may be due to the pathology in the cranial abdomen since the sternal lymph node drains part of the cranial abdomen. Infiltrative pathology, however, cannot be ruled out entirely. Consider surgical exploration as well as comprehensive sampling.

SEX

MN

AGE

5

INTERPRETED BY

Nele Eley, DVM
Dr. med. Vet. DipECVDI

HOSPITAL NAME

Northeast Veterinary
Referral Hospital

REFERRING VET

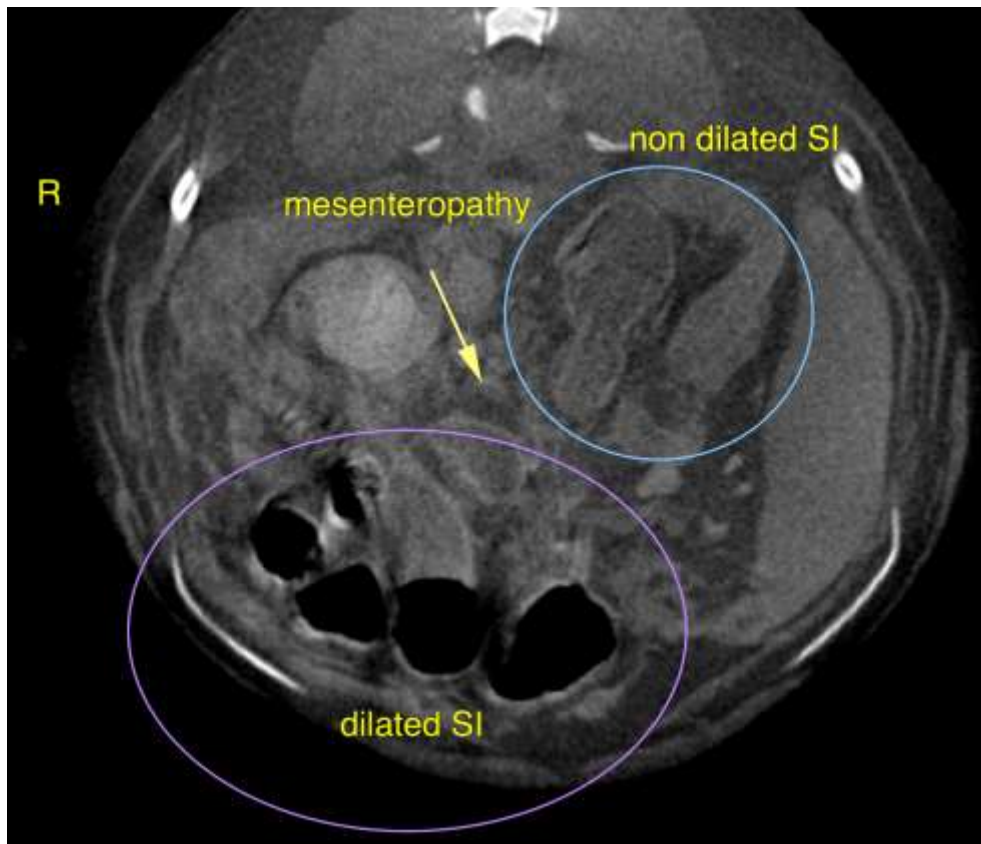
Dr. Runde

INVOICE

47521

DATE

9-24-21





PATIENT

Jedi Rook

The information and recommendations provided are based on the images presented by the referring veterinarian. No evaluation can be communicated regarding pathology that was not visible in the image/video clips provided.

Thank you for this referral. If the clinical or image interpretation does not parallel your findings or if I can be of any further assistance please contact me.

SPECIES

Canine

Nele Eley, DVM, Dr. med. vet., DipECVDI
European Specialist in Veterinary Diagnostic Imaging, Cert. Radiology,
Senior lecturer University of Giessen, Germany, Veterinary Faculty, Department of Radiology
Nele.Eley@sonopath.com

BREED

Labrador Retriever

SEX

MN

AGE

5

INTERPRETED BY

Nele Eley, DVM
Dr. med. Vet. DipECVDI

HOSPITAL NAME

Northeast Veterinary
Referral Hospital

REFERRING VET

Dr. Runde

INVOICE

47521

DATE

9-24-21