



PATIENT

PRESENTING CLINICAL SIGNS

Wheeler Litzenburg

LH lameness. Suspect Partial CCL injury
Abnormal PE/Chem/CBC/UA Results: WNL

SPECIES

ULTRASONOGRAPHIC FINDINGS

Canine

Left Stifle

BREED

No significant effusion is seen within the infrapatellar recess of the left stifle joint. Patella tendon and infrapatellar fat pad present within normal limits.

Heeler Cross

The cranial cruciate ligament appears to be thick and hypoechoic, yet it presents clearly delineated margins and is continuous.

SEX

ULTRASONOGRAPHIC DIAGNOSIS

FS

- Swelling and slightly altered echogenicity of the continuous left cranial cruciate ligament.

AGE

INTERPRETATION OF THE FINDINGS & FURTHER RECOMMENDATIONS

6 Years

Fiber disruption of the left cranial cruciate ligament cannot be identified. There appears to be significant swelling of the left cranial cruciate ligament which may represent edema or emerging partial rupture. However, with the ultrasonographic findings, I am not fully confident that there is significant cruciate ligament injury with biomechanical failure of the ligament. Correlation with the clinical palpation is required and clinical as well as ultrasonographic monitoring could be considered along with conservative management.

INTERPRETED BY

Nele Eley, DVM
Dr. med. Vet. DipECVDI

HOSPITAL NAME

Foxfield Veterinary
Services

REFERRING VET

A, Rodriguez

INVOICE

54220

DATE

9-23-22



PATIENT

Wheeler Litzenburg

SPECIES

Canine

BREED

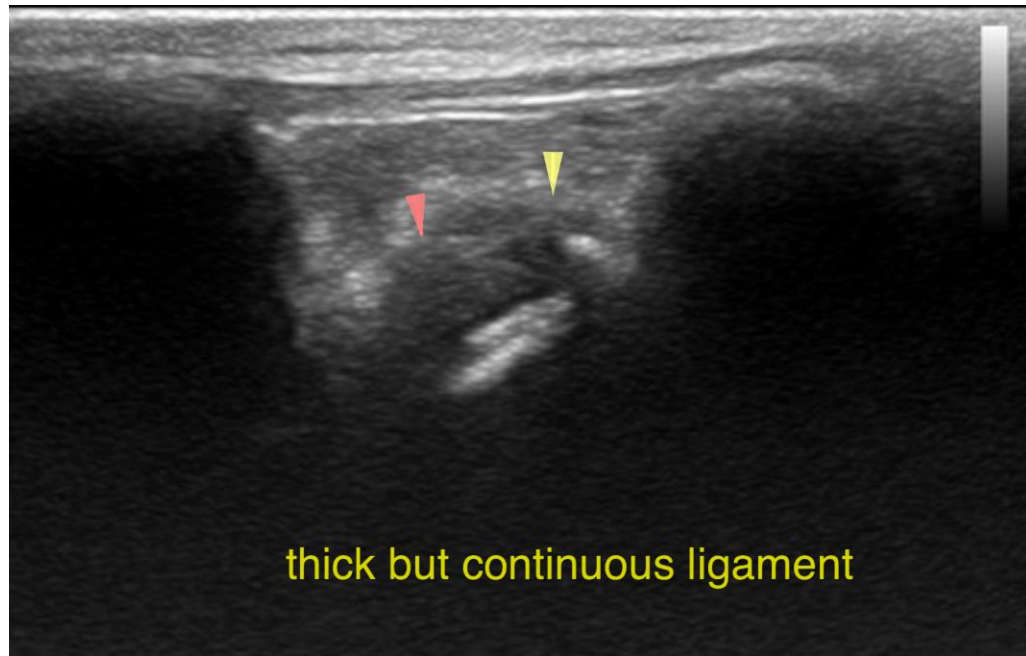
Heeler Cross

SEX

FS

AGE

6 Years



INTERPRETED BY

Nele Eley, DVM
Dr. med. Vet. DipECVDI

The information and recommendations provided are based on the images presented by the referring veterinarian/sonographer. No evaluation can be communicated regarding pathology that was not visible in the image/video clips provided.

Thank you for this referral. If the clinical or image interpretation does not parallel your findings or if I can be of any further assistance please contact me.

HOSPITAL NAME

Foxfield Veterinary
Services

Nele Eley, DVM, Dr. med. vet., DipECVDI
European Specialist in Veterinary Diagnostic Imaging, Cert. Radiology,
Senior lecturer University of Giessen, Germany, Veterinary Faculty, Department of Radiology
Nele.Eley@sonopath.com

REFERRING VET

A, Rodriguez

INVOICE

54220

DATE

9-23-22