



PATIENT PRESENTING CLINICAL SIGNS

Rusty Wender 3 day history of progressive facial swelling ventral to R eye, noted swelling with possible draining tract tooth 108. Dental radiographs revealed mild root resorption, otherwise WNL. Swelling significantly resolved following antibiotics.

SPECIES

Canine

Abnormal PE/Chem/CBC/UA Results: PE- Draining tract along free gingiva tooth 108, no grass awn extracted.

COMPUTED TOMOGRAPHIC STUDY OF THE DENTAL ARCADES

BREED

Standard Poodle

Plain study available for review. Part of the nasal cavities included.

COMPUTED TOMOGRAPHIC FINDINGS

SEX

Neutered Male

Left-sided facial swelling level with the rostral aspect of the zygomatic arch and along the left maxilla is noted.

AGE

10 Years

There is no evidence of significant dental disease. No tooth root abscessation and no osseous changes of the alveolar margin or maxilla are seen.

A moderate amount of fluid attenuating material is seen within the left nasal cavity. A mild amount of fluid attenuating material is present within the right nasal cavity. No evidence of foreign material or turbinate destruction noted.

COMPUTED TOMOGRAPHIC DIAGNOSIS

INTERPRETED BY

Nele Eley (Ondreka),
DVM Dr. med. vet.,
DipECVDI

- Unspecific soft tissue swelling in the left intraorbital area
- Bilateral non-destructive rhinitis
- No evidence of significant dental disease

INTERPRETATION OF FINDINGS & FURTHER RECOMMENDATIONS

HOSPITAL NAME

Healing Spirit

Dental disease does not appear to be the underlying cause of the facial swelling in the left intraorbital area. Parotid duct involvement cannot be ruled out entirely. However, cellulitis, hematoma, and less likely abscess, granuloma, cyst, and early neoplasia cannot be ruled out entirely as differential diagnoses. Note the presence of bilateral non-destructive rhinitis. Differential diagnoses include allergic or infectious rhinitis such as viral or bacterial.

REFERRING VET

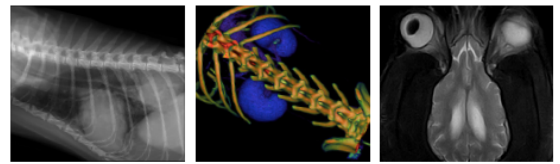
Dr. Desen Ertunc

INVOICE

41624

DATE

9/22/22



PATIENT

Rusty Wender

SPECIES

Canine

BREED

Standard Poodle

SEX

Neutered Male

AGE

10 Years

INTERPRETED BY

Nele Eley (Ondreka),
DVM Dr. med. vet.,
DipECVDI

HOSPITAL NAME

Healing Spirit

REFERRING VET

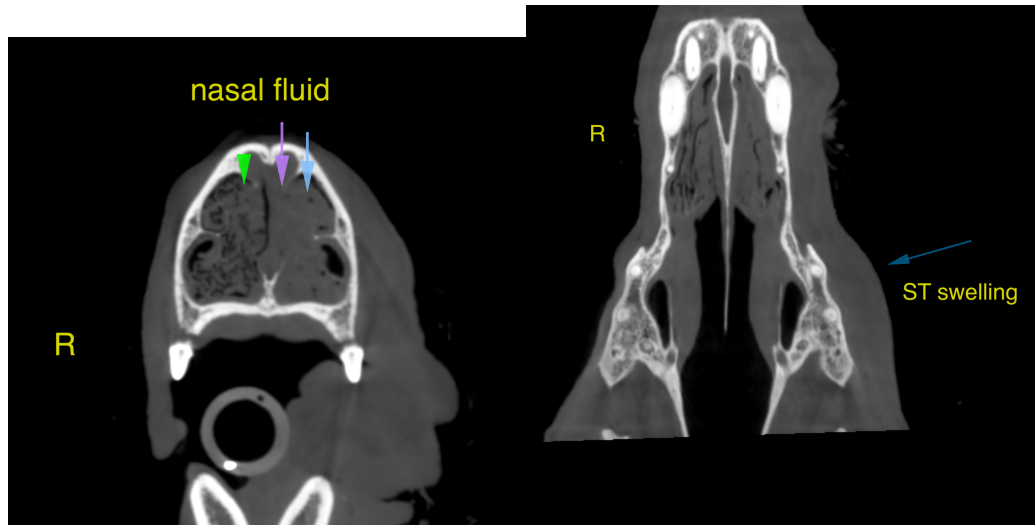
Dr. Desen Ertunc

INVOICE

41624

DATE

9/22/22



The information and recommendations provided are based on the images presented by the referring veterinarian. No evaluation can be communicated regarding pathology that was not visible in the image/video clips provided.

Thank you for this referral. If the clinical or image interpretation does not parallel your findings or if I can be of any further assistance please contact me.

Nele Eley (Ondreka), DVM, Dr. med. vet., DipECVDI
European Specialist in Veterinary Diagnostic Imaging, Cert. Radiology,
Senior lecturer University of Giessen/Germany, Veterinary Faculty, Department of Radiology.
Nele.Eley@sonopath.com