



PATIENT

Kyla Collins

PRESENTING CLINICAL SIGNS

Excessive panting, Rest of PE is normal. sleep RR= 84/ min no current medications
Abnormal PE/Chem/CBC/UA Results: Triglycerides= 504 mg/dl rest is in WNL urinalyses is normal Specific Gravity: 1.027

SPECIES

Canine

RADIOGRAPHIC STUDY OF THE THORAX

Left lateral and ventrodorsal views of the thorax totaling 2 images available for review.

BREED

Papillon Mix

RADIOGRAPHIC FINDINGS

Mild spondyloses are seen between T6/7, T7/8, and within the cranial lumbar spine.

SEX

FS

The degree of pulmonary inflation is moderate. A mild generalized bronchial lung pattern is noted.

Course and width of the trachea are considered within normal limits.

There is mild upper esophageal aerophagia which is an incidental finding.

AGE

9 Years

The vertebra heart score is 10.5. No specific chamber enlargement is seen. There is no evidence of a vascular lung pattern or congestive heart failure.

There is no evidence of mediastinal widening.

Moderate generalized enlargement of the liver is noted.

INTERPRETED BY

Nele Eley, DVM
Dr. med. Vet. DipECVDI

RADIOGRAPHIC DIAGNOSIS

- Mild bronchial lung pattern.
- No radiographic evidence of cardiovascular pathology.
- Moderate hepatomegaly.
- Mild spondyloses.

HOSPITAL NAME

Byram Animal
Hospital

INTERPRETATION OF THE FINDINGS & FURTHER RECOMMENDATIONS

A mild bronchial lung pattern is noted. The findings may be within age related normal limits however low grade lower airway disease such as eosinophilic/allergic bronchopneumopathy or infectious bronchitis cannot be ruled out entirely. The radiographic findings do not seem to fully explain the patient's clinical signs, especially in the absence of coughing.

Systemic metabolic disease, endocrinopathy, and systemic infection as well as central nervous systemic disease should be ruled out.

REFERRING VET

Dr. Carlos Abdul-Chani

INVOICE

54254

The hepatomegaly may be due to vacuolar, metabolic, endocrine hepatopathy. Diffuse infiltration with inflammatory cells or round cells cannot be ruled out entirely but is thought not likely to correlate with the laboratory values.

DATE

9-23-22



PATIENT

Kyla Collins

SPECIES

Canine

BREED

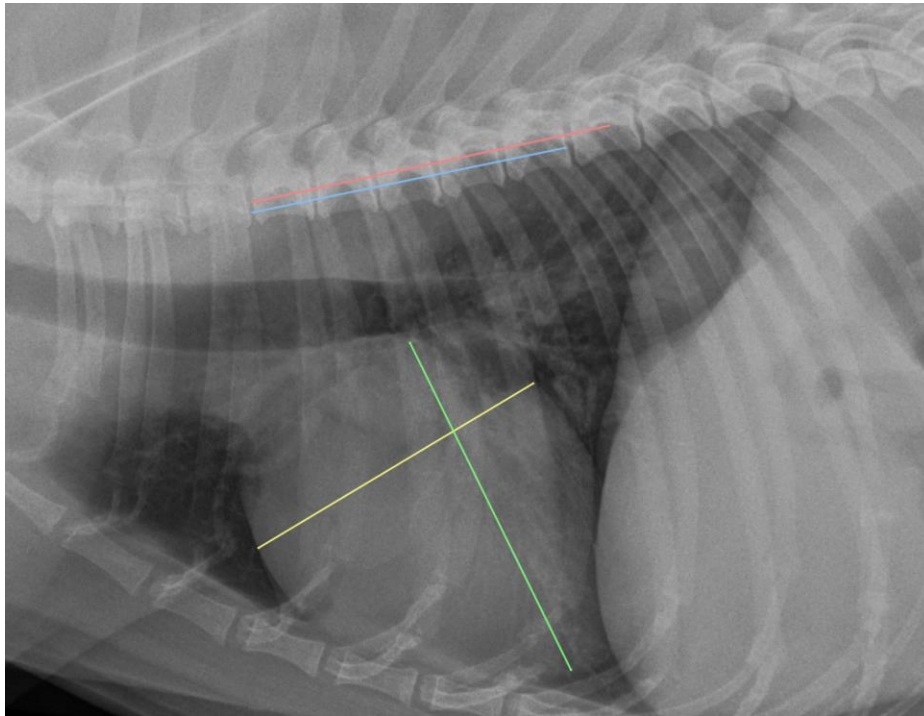
Papillon Mix

SEX

FS

AGE

9 Years



INTERPRETED BY

Nele Eley, DVM
Dr. med. Vet. DipECVDI

The information and recommendations provided are based on the images presented by the referring veterinarian/sonographer. No evaluation can be communicated regarding pathology that was not visible in the image/video clips provided.

Thank you for this referral. If the clinical or image interpretation does not parallel your findings or if I can be of any further assistance please contact me.

HOSPITAL NAME

Byram Animal
Hospital

Nele Eley, DVM, Dr. med. vet., DipECVDI
European Specialist in Veterinary Diagnostic Imaging, Cert. Radiology,
Senior lecturer University of Giessen, Germany, Veterinary Faculty, Department of Radiology
Nele.Eley@sonopath.com

REFERRING VET

Dr. Carlos Abdul-
Chani

INVOICE

54254

DATE

9-23-22