



PATIENT

Katelyn Kamisar

SPECIES

Canine

BREED

Great Pry

SEX

Male

AGE

4 Years

INTERPRETED BY

Nele Eley, DVM
Dr. med. Vet. DipECVDI

HOSPITAL NAME

Gentle Doctor Animal
Hospital

REFERRING VET

Sydney Thorson

INVOICE

54250

DATE

9-23-22

PRESENTING CLINICAL SIGNS

Intermittent difficulty rising from laying down for the past year that appears worse after longer periods of laying down. Occasionally seems to favor a hind leg (owner believes left hind). No other changes noted at home.

Abnormal PE/Chem/CBC/UA Results: Mild decrease of muscle mass in left hind compared to right. No cranial drawer appreciated.

RADIOGRAPHIC STUDY OF THE PELVIS

2 ventrodorsal images of the pelvis and 2 mediolateral views of the stifles are available for review.

Pelvic read requested.

There is no side marker on the images of the pelvis. The side with the hind limb muscle atrophy comes up as the right side in my Dicom viewer, however, based on the submission form, this appears to represent the left side.

RADIOGRAPHIC FINDINGS

Unilateral hind limb muscle atrophy is seen in the radiographic study of the pelvis.

The coxofemoral joints present within normal limits. Minimal joint space divergence and slightly reduced femoral head coverage is seen bilaterally however there is no significant evidence of coxofemoral joint osteoarthritis.

RADIOGRAPHIC DIAGNOSIS

- Borderline hip dysplasia of both coxofemoral joints with minimal osteoarthritic changes.
- Unilateral hind limb muscle atrophy, presumably on the left – neurogenic versus disuse.

INTERPRETATION OF THE FINDINGS & FURTHER RECOMMENDATIONS

A definitive underlying cause of the lameness cannot be identified on the radiographic study of the pelvis. The borderline signs of hip dysplasia and minimal osteoarthritic changes are bilaterally symmetric and unlikely to justify clinical lameness even though this cannot be ruled out entirely. Consider soft tissue trauma or inflammation as well as neurologic disease as potential causes of the patient's clinical signs.



PATIENT

Katelyn Kamisar

SPECIES

Canine

BREED

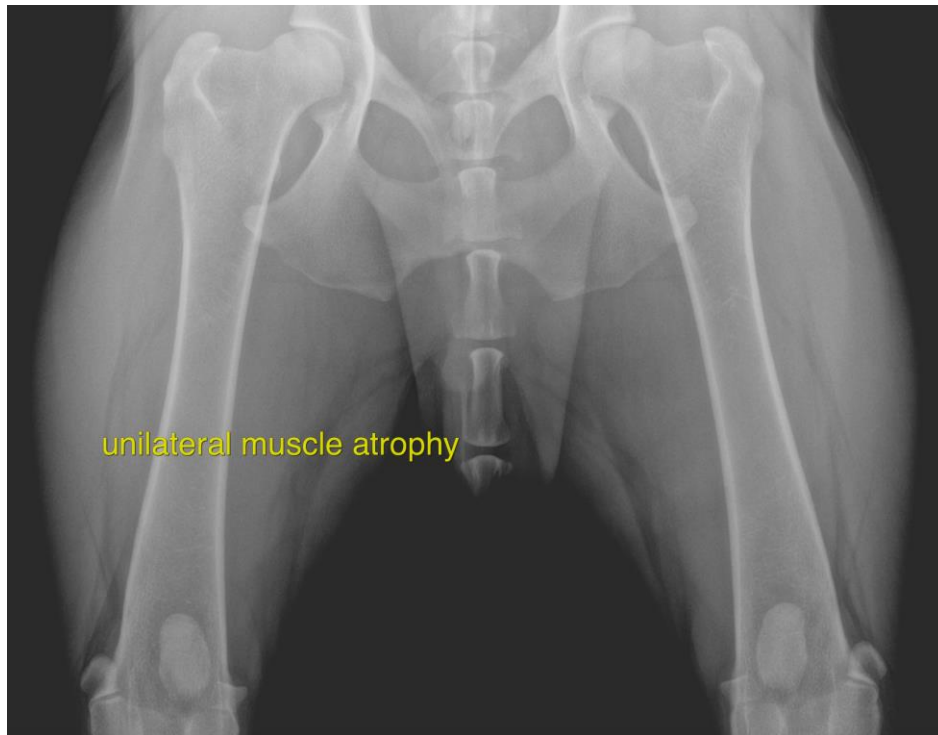
Great Pry

SEX

Male

AGE

4 Years



INTERPRETED BY

Nele Eley, DVM
Dr. med. Vet. DipECVDI

The information and recommendations provided are based on the images presented by the referring veterinarian/sonographer. No evaluation can be communicated regarding pathology that was not visible in the image/video clips provided.

HOSPITAL NAME

Gentle Doctor Animal
Hospital

Thank you for this referral. If the clinical or image interpretation does not parallel your findings or if I can be of any further assistance please contact me.

Nele Eley, DVM, Dr. med. vet., DipECVDI
European Specialist in Veterinary Diagnostic Imaging, Cert. Radiology,
Senior lecturer University of Giessen, Germany, Veterinary Faculty, Department of Radiology
Nele.Eley@sonopath.com

REFERRING VET

Sydney Thorson

INVOICE

54250

DATE

9-23-22