



PATIENT

Honey Davenport

PRESENTING CLINICAL SIGNS

Right orbital disease resulting in dorsal lateral strabismus and reduced retropulsion and reduced nasal airflow on right side. Did not improve with previous oral antiinflammatory and antibiotic treatment. She has a history of previous subcutaneous hemangiosarcoma removed in 2022 (no metastasis check has been done). Seen for initial exam with us on 9/15/22, did CBC/Chemistry and referred for single site skull CT with contrast due to concern for neoplasia. Rule out: Orbital neoplasia +/- nasal involvement - right side

SPECIES

Canine

COMPUTED TOMOGRAPHIC STUDY OF THE HEAD

BREED

Rat Terrier

Plain and post contrast studies available for review. Study is right/left flipped.

COMPUTED TOMOGRAPHIC FINDINGS

SEX

RFS

A heterogeneously enhancing ovoid soft tissue mass is seen in the ventral nasal aspect of the left orbita. The mass measures approximately 2.5 cm in diameter. A mass effect onto the orbital tissues and left eye is seen causing a mild left sided exophthalmos. Early osteolytic changes of the left pterygoid and frontal bone are seen. At this time, there is no evidence of intracranial invasion.

AGE

15 Years

The regional submandibular and retropharyngeal lymph nodes present within normal limits.

COMPUTED TOMOGRAPHIC DIAGNOSIS

- Large soft tissue mass meeting neoplastic criteria within the left orbita with left sided exophthalmos.

INTERPRETED BY

Nele Eley, DVM
Dr. med. Vet. DipECVDI

INTERPRETATION OF THE FINDINGS & FURTHER RECOMMENDATIONS

The CT findings are highly suggestive for a soft tissue mass with aggressive biological behavior within the left orbita which causes early aggressive bone lysis of the left frontal and left pterygoid bones. Differential diagnosis includes adenocarcinoma, soft tissue sarcoma, and less likely meningioma, adenoma, or other. The findings are not typical for an abscess or granuloma. Final diagnosis will require sampling for histology. Sampling could be attempted under ultrasonographic guidance using a temporal window. At this time, there is no evidence of metastatic disease of the regional lymph nodes.

HOSPITAL NAME

Advanced Animal
Imaging

REFERRING VET

Blair Hollowell, DVM

INVOICE

54255

DATE

9-23-22



PATIENT

Honey Davenport

SPECIES

Canine

BREED

Rat Terrier

SEX

RFS

AGE

15 Years

INTERPRETED BY

Nele Eley, DVM
Dr. med. Vet. DipECVDI

HOSPITAL NAME

Advanced Animal
Imaging

REFERRING VET

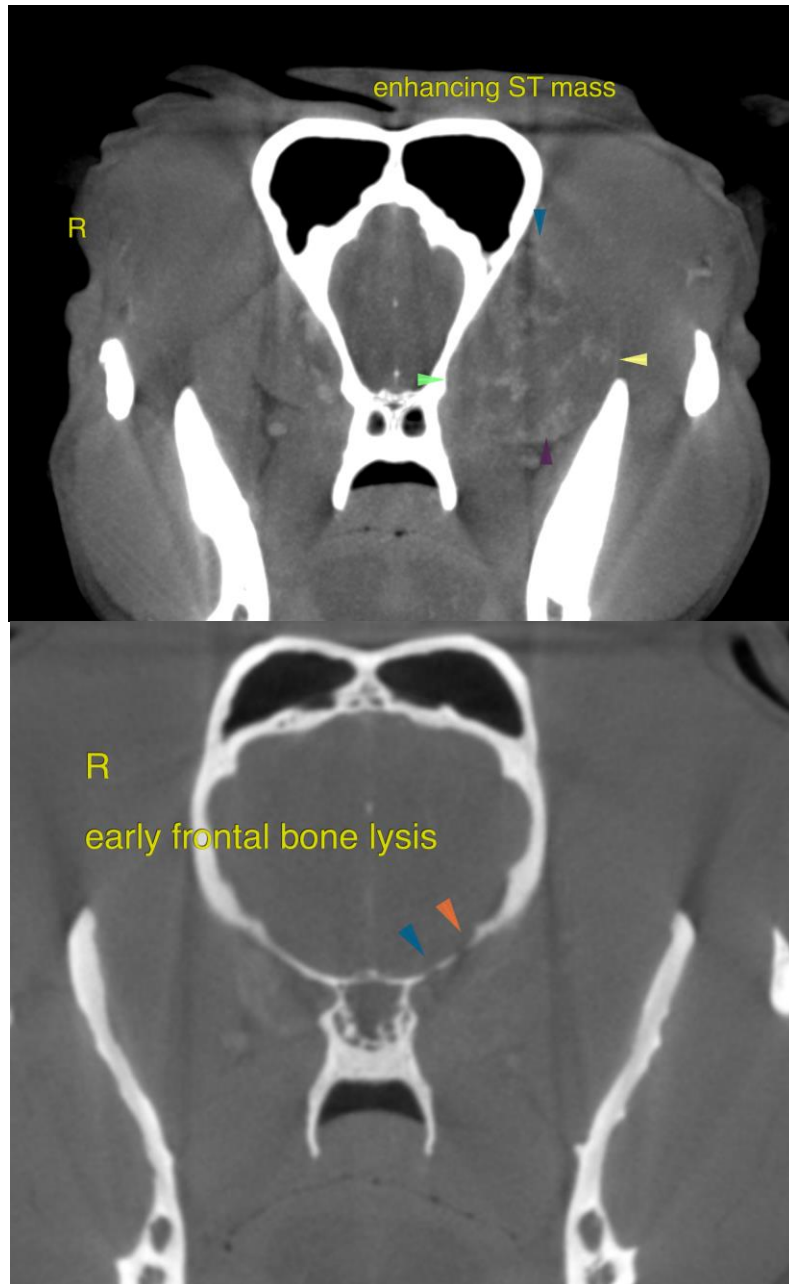
Blair Hollowell, DVM

INVOICE

54255

DATE

9-23-22





PATIENT

Honey Davenport

The information and recommendations provided are based on the images presented by the referring veterinarian/sonographer. No evaluation can be communicated regarding pathology that was not visible in the image/video clips provided.

SPECIES

Canine

Thank you for this referral. If the clinical or image interpretation does not parallel your findings or if I can be of any further assistance please contact me.

BREED

Rat Terrier

Nele Eley, DVM, Dr. med. vet., DipECVDI
European Specialist in Veterinary Diagnostic Imaging, Cert. Radiology,
Senior lecturer University of Giessen, Germany, Veterinary Faculty, Department of Radiology
Nele.Eley@sonopath.com

SEX

RFS

AGE

15 Years

INTERPRETED BY

Nele Eley, DVM
Dr. med. Vet. DipECVDI

HOSPITAL NAME

Advanced Animal
Imaging

REFERRING VET

Blair Hollowell, DVM

INVOICE

54255

DATE

9-23-22