

**PATIENT**

Bamboo Garcia

**PRESENTING CLINICAL SIGNS**

Presented for baseball sized abscess over R mandible. Severe lip and cheek swelling R side, unable to open mouth due to severe swelling. Significant dental calculus and gingivitis on visible teeth on L side of mouth.

**SPECIES**

Feline

**COMPUTED TOMOGRAPHIC STUDY OF THE HEAD**

Plain study available for review.

**BREED**

DSH

**COMPUTED TOMOGRAPHIC FINDINGS**

Assessment of the soft tissues is limited to the availability of a plain study.

**SEX**

MN

There is extensive soft tissue swelling ventral and lateral of the right mandible with diffuse emphysema. No overt aggressive bone lesions of the mandibular are seen; however, there is heterogeneous multifocal medullary sclerosis of the right mandibular body.

**AGE**

18 Years

The dentition is incomplete. Multiple teeth are absent. The remaining teeth present multifocal moderate to severe resorptive defects.

A moderate amount of hypoattenuating material is present within the horizontal parts of both external auditory meatuses.

**INTERPRETED BY**

Nele Eley, DVM  
Dr. med. Vet. DipECVDI

The lymph nodes cannot be delineated exactly but there appears to be regional lymphadenomegaly.

**COMPUTED TOMOGRAPHIC DIAGNOSIS**

- Cavitary lesion with emphysema and diffuse soft tissue swelling ventral and lateral of the right mandible.
- Right mandibular medullary sclerosis.
- Incomplete dentition with FORL.
- Bilateral otitis externa.
- Presumed regional lymphadenomegaly.

**HOSPITAL NAME**

South Bay Animal  
Hospital & Pet Resort

**INTERPRETATION OF THE FINDINGS & FURTHER RECOMMENDATIONS****REFERRING VET**

Dr. Rupashree Rao

The CT findings are compatible with the history of abscess. No foreign material is seen. The delineation of the soft tissue changes is limited owing to the availability of a plain study only.

**INVOICE**

47529

The findings of the right mandible are compatible with osteitis. No overt aggressive bone lesions are seen. However, owing to the patient's age, tumor with central necrosis should be ruled out by means of histology regardless.

**DATE**

9-23-21



**PATIENT**

Bamboo Garcia

**SPECIES**

Feline

**BREED**

DSH

**SEX**

MN

**AGE**

18 Years

**INTERPRETED BY**

Nele Eley, DVM  
Dr. med. Vet. DipECVDI

**HOSPITAL NAME**

South Bay Animal  
Hospital & Pet Resort

**REFERRING VET**

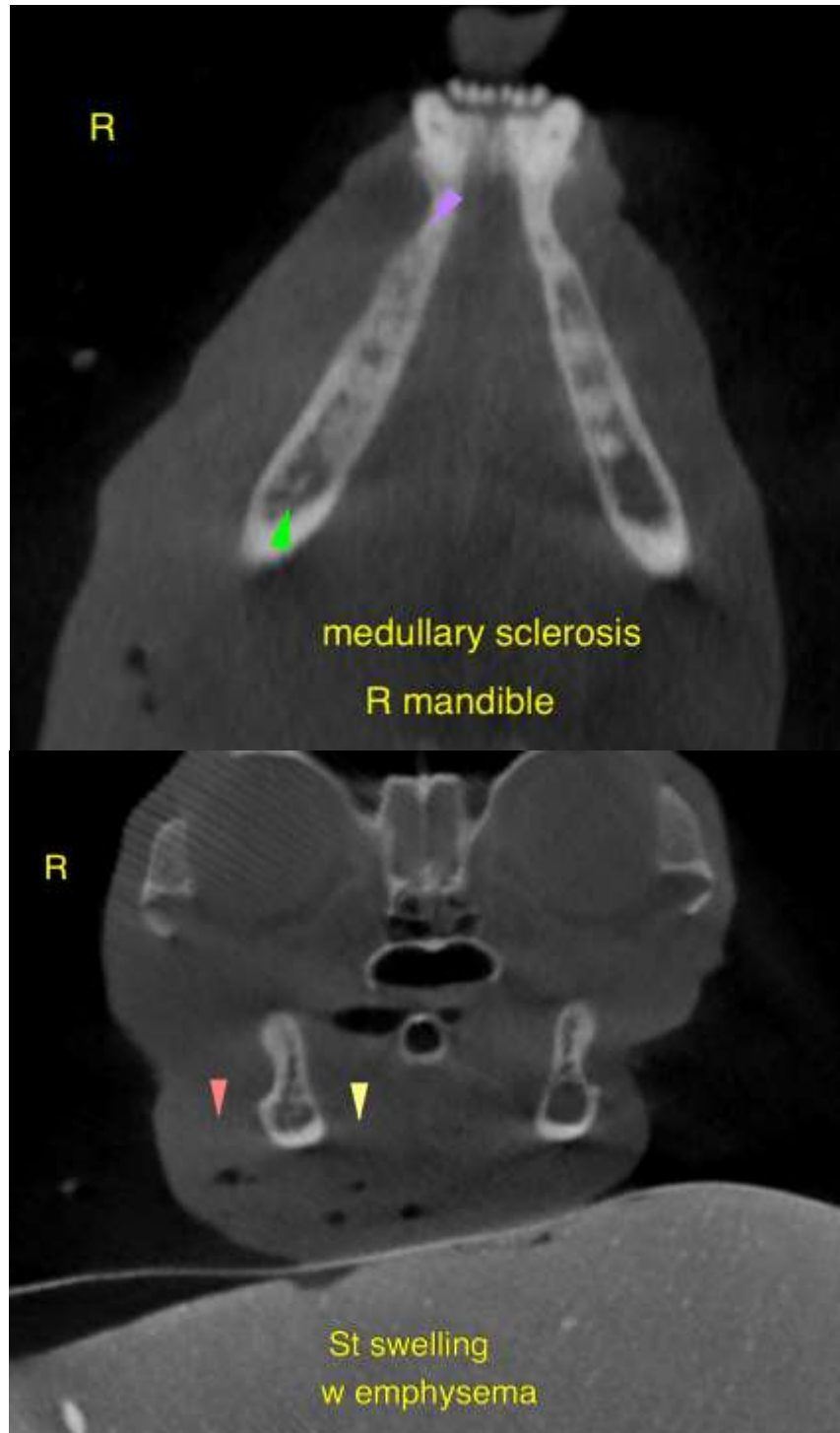
Dr. Rupashree Rao

**INVOICE**

47529

**DATE**

9-23-21





**PATIENT**

Bamboo Garcia

The information and recommendations provided are based on the images presented by the referring veterinarian. No evaluation can be communicated regarding pathology that was not visible in the image/video clips provided.

Thank you for this referral. If the clinical or image interpretation does not parallel your findings or if I can be of any further assistance please contact me.

**SPECIES**

Feline

**Nele Eley**, DVM, Dr. med. vet., DipECVDI  
European Specialist in Veterinary Diagnostic Imaging, Cert. Radiology,  
Senior lecturer University of Giessen, Germany, Veterinary Faculty, Department of Radiology  
Nele.Eley@sonopath.com

**BREED**

DSH

**SEX**

MN

**AGE**

18 Years

**INTERPRETED BY**

Nele Eley, DVM  
Dr. med. Vet. DipECVDI

**HOSPITAL NAME**

South Bay Animal  
Hospital & Pet Resort

**REFERRING VET**

Dr. Rupashree Rao

**INVOICE**

47529

**DATE**

9-23-21