

PATIENT

Zeus Miller

PRESENTING CLINICAL SIGNS

2nd opinion Presented to rdvm last week for lame in rear end/left leg non weight bearing, limping, pain. xrays performed, galliprant sent home. The next day o notes pt unable to swallow. returned to rdvm xrays performed, mass in throat noted, clindamycin sent for possible salivary gland infection. mild improvement after starting meds, still pt is unable to swallow comfortably, decreased app, depressed.

SPECIES

Canine

Abnormal PE/Chem/CBC/UA Results: rDVM PE notes: Gagging on tracheal palpation. Large, irregular firm swelling on cranio-ventral aspect of cervical region. Multiple soft, different sizes, SQ masses - most likely lipomas.

BREED

Shepherd Mix

COMPUTED TOMOGRAPHIC STUDY OF THE NECK

Plain and post contrast studies available for review.

SEX

Male Neutered

COMPUTED TOMOGRAPHIC FINDINGS

Mild regional swelling of the left sternothyroid muscle is seen ventral of the left lobe of the thyroid gland. The diameter of the muscle is increased to 7mm compared with 4mm on the right side and the muscle is mildly rounded in appearance and cross section.

AGE

10 Years

There appears to be mild dorsal deviation of the left lobe of the thyroid gland; however, both lobes of the thyroid gland present within normal limits in terms of their position, size, shape, and plain and post contrast attenuation.

INTERPRETED BY

Nele Eley, DVM
Dr. med. Vet. DipECVDI

Both medial retropharyngeal lymph nodes present mild symmetric swelling with maintained short-to-long-axis ratio and maintained contrast enhancement patterns.

The submandibular and cervical lymph nodes present within normal limits.

The salivary glands present within normal limits.

HOSPITAL NAME

Mobile Pet Imaging

There is mild generalized swelling of the laryngeal soft tissues and upper esophageal sphincter. The esophagus contains a mild amount of gas and a mild amount of fluid.

REFERRING VET

Meaux

Number, alignment, and anatomy of the cervical vertebrae present within normal limits. No evidence of compressive myelopathy is seen.

COMPUTED TOMOGRAPHIC DIAGNOSIS

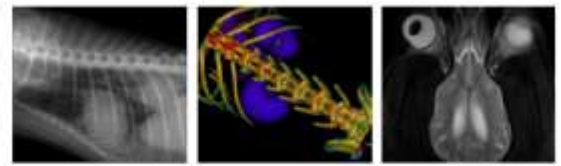
- Mild regional swelling of the left sternothyroid muscle of undetermined origin and significance.
- No evidence of a discreet mass in the neck.
- Structurally normal CT study of the thyroid gland.
- Mild bilateral medial retropharyngeal lymphadenomegaly.
- Mild laryngeal soft tissue swelling.

INVOICE

47503

DATE

9-22-21



PATIENT

Zeus Miller

SPECIES

Canine

BREED

Shepherd Mix

SEX

Male Neutered

AGE

10 Years

INTERPRETED BY

Nele Eley, DVM
Dr. med. Vet. DipECVDI

HOSPITAL NAME

Mobile Pet Imaging

REFERRING VET

Meaux

INVOICE

47503

DATE

9-22-21

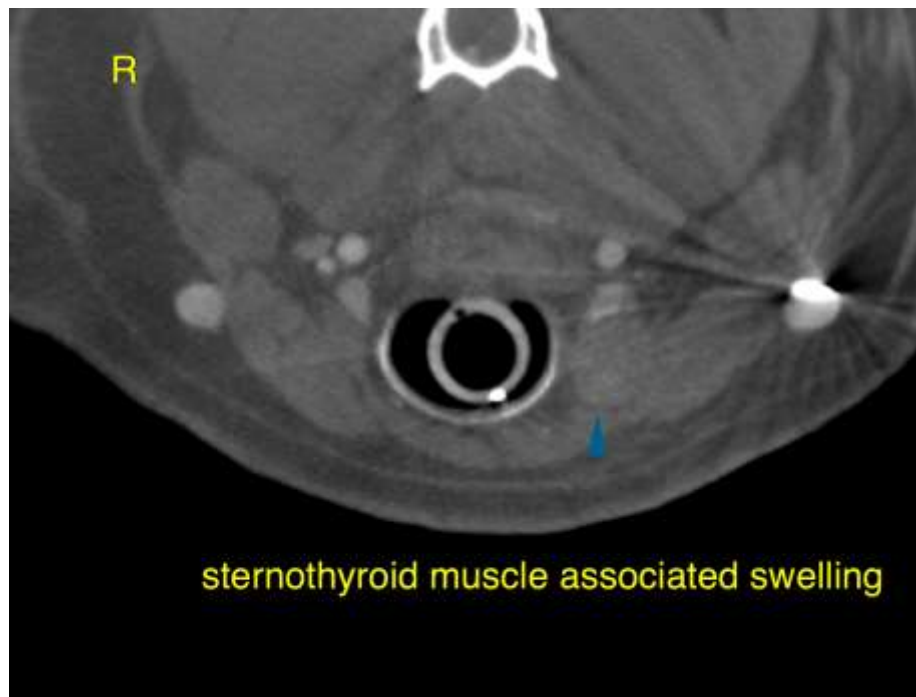
INTERPRETATION OF THE FINDINGS & FURTHER RECOMMENDATIONS

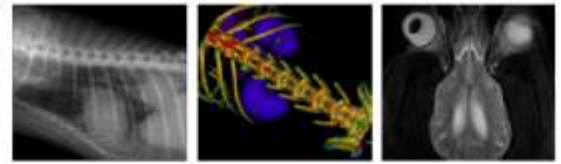
No discreet mass is seen in the neck. The mild regional sternothyroid muscle swelling may be positional and incidental; however, nodular enlargement due to hematoma, edema, inflammation, or early neoplasia cannot be ruled out entirely and ultrasound guided fine needle aspiration could be considered for further definition.

Differential diagnosis for the mild retropharyngeal lymphadenomegaly includes reactive hyperplasia and less likely neoplastic infiltrate. Consider fine needle aspiration for further definition.

The CT study of the thyroid and salivary glands was within normal limits.

The mild laryngeal soft tissue swelling is suggestive for either edema or inflammation.





PATIENT

Zeus Miller

SPECIES

Canine

BREED

Shepherd Mix

SEX

Male Neutered

AGE

10 Years

INTERPRETED BY

Nele Eley, DVM
Dr. med. Vet. DipECVDI

HOSPITAL NAME

Mobile Pet Imaging

REFERRING VET

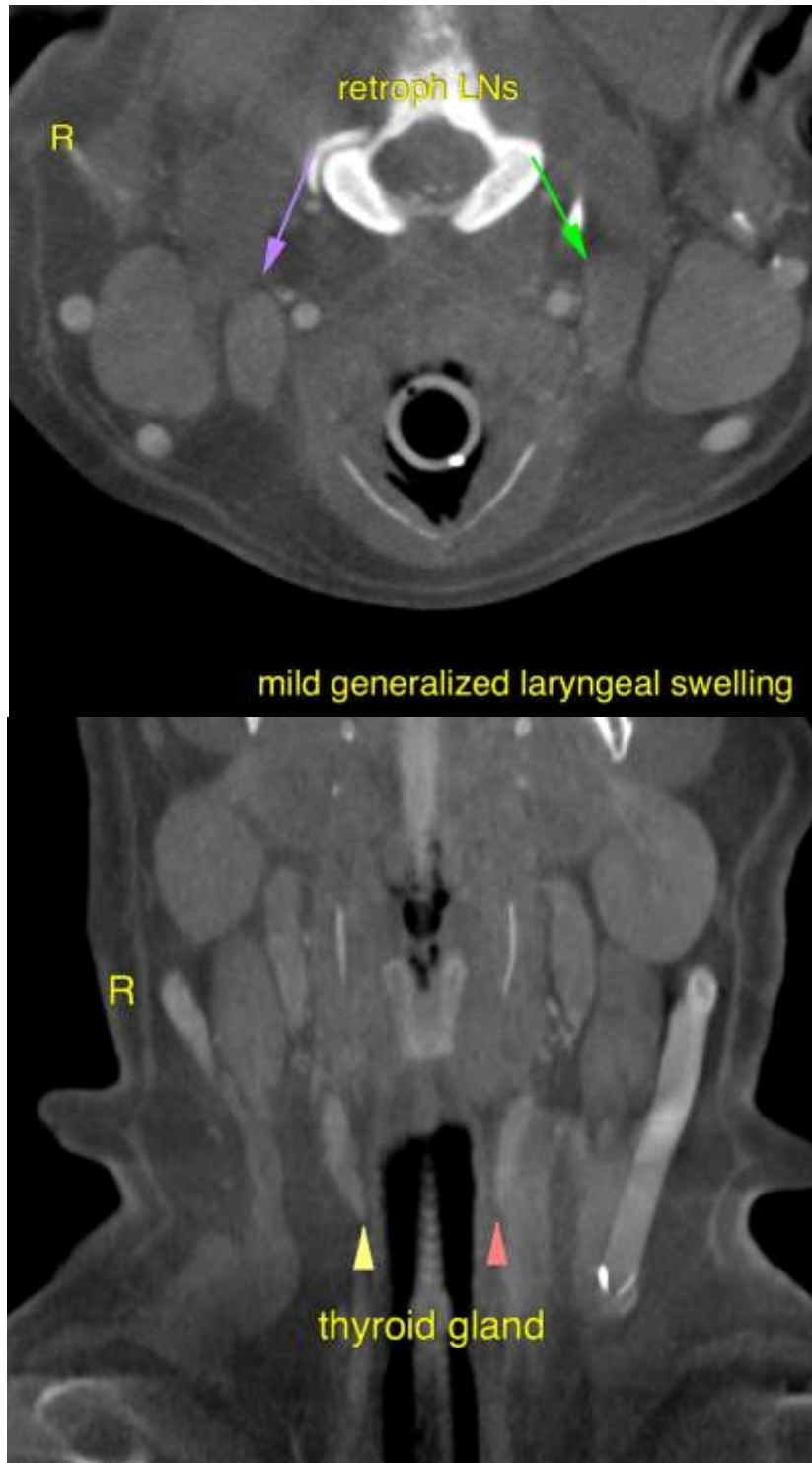Meaux

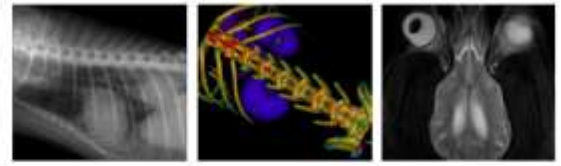
INVOICE

47503

DATE

9-22-21





PATIENT

Zeus Miller

The information and recommendations provided are based on the images presented by the referring veterinarian. No evaluation can be communicated regarding pathology that was not visible in the image/video clips provided.

SPECIES

Canine

Thank you for this referral. If the clinical or image interpretation does not parallel your findings or if I can be of any further assistance please contact me.

BREED

Shepherd Mix

Nele Eley, DVM, Dr. med. vet., DipECVDI
European Specialist in Veterinary Diagnostic Imaging, Cert. Radiology,
Senior lecturer University of Giessen, Germany, Veterinary Faculty, Department of Radiology
Nele.Eley@sonopath.com

SEX

Male Neutered

AGE

10 Years

INTERPRETED BY

Nele Eley, DVM
Dr. med. Vet. DipECVDI

HOSPITAL NAME

Mobile Pet Imaging

REFERRING VET

Meaux

INVOICE

47503

DATE

9-22-21