

**PATIENT**

Sugar Boy White

PRESENTING CLINICAL SIGNS

Possible nasal airway obstruction causing green nasal discharge; r/o polyp P has been having respiratory problems for the last 4 years.

SPECIES

Feline

COMPUTED TOMOGRAPHIC STUDY OF THE NECK

Post contrast study only available for review. The head is not fully imaged.

BREED

DLH

COMPUTED TOMOGRAPHIC FINDINGS

Moderate even thickening of the bony wall of the left tympanic bulla is seen. There is mucosal swelling and mild fluid accumulation within the left tympanic bulla.

SEX

NM

A soft tissue attenuating mass with lobulated appearance is obstructing and expanding the nasopharynx. The mass measures approximately 2.5 cm in length, 2.0 cm in width, and 1.5 cm in height and presents a stalk-like extension into the left auditory tube. The patent lumen of the nasopharynx contains a moderate amount of fluid attenuating material.

Both tonsils are enlarged and everted.

AGE

5 Years

The left medial retropharyngeal lymph node presents mild symmetric enlargement with maintained short-to-long-axis-ratio and maintained contrast enhancement pattern.

INTERPRETED BY

Nele Eley, DVM
Dr. med. Vet. DipECVDI

COMPUTED TOMOGRAPHIC DIAGNOSIS

- Chronic left sided otitis media with presumed nasopharyngeal polyp formation.
- Bilateral tonsillitis.
- Left medial retropharyngeal lymphadenomegaly.

HOSPITAL NAME

Paws and Claws
Urgent Care

INTERPRETATION OF THE FINDINGS & FURTHER RECOMMENDATIONS

The CT findings are highly suggestive for left sided otitis media with chronic inflammatory nasopharyngeal polyp formation. The multilobulated appearance of the mass is somewhat atypical for a nasopharyngeal polyp, hence histology of the mass is strongly recommended after removal in order to rule out malignant transformation.

REFERRING VET

Dr. Juarez

The lymph node changes are compatible with reactive hyperplasia. Early metastatic disease cannot be ruled out entirely but is considered by far less likely.

INVOICE

9-22-21

DATE



PATIENT

Sugar Boy White

SPECIES

Feline

BREED

DLH

SEX

NM

AGE

5 Years

INTERPRETED BY

Nele Eley, DVM
Dr. med. Vet. DipECVDI

HOSPITAL NAME

Paws and Claws
Urgent Care

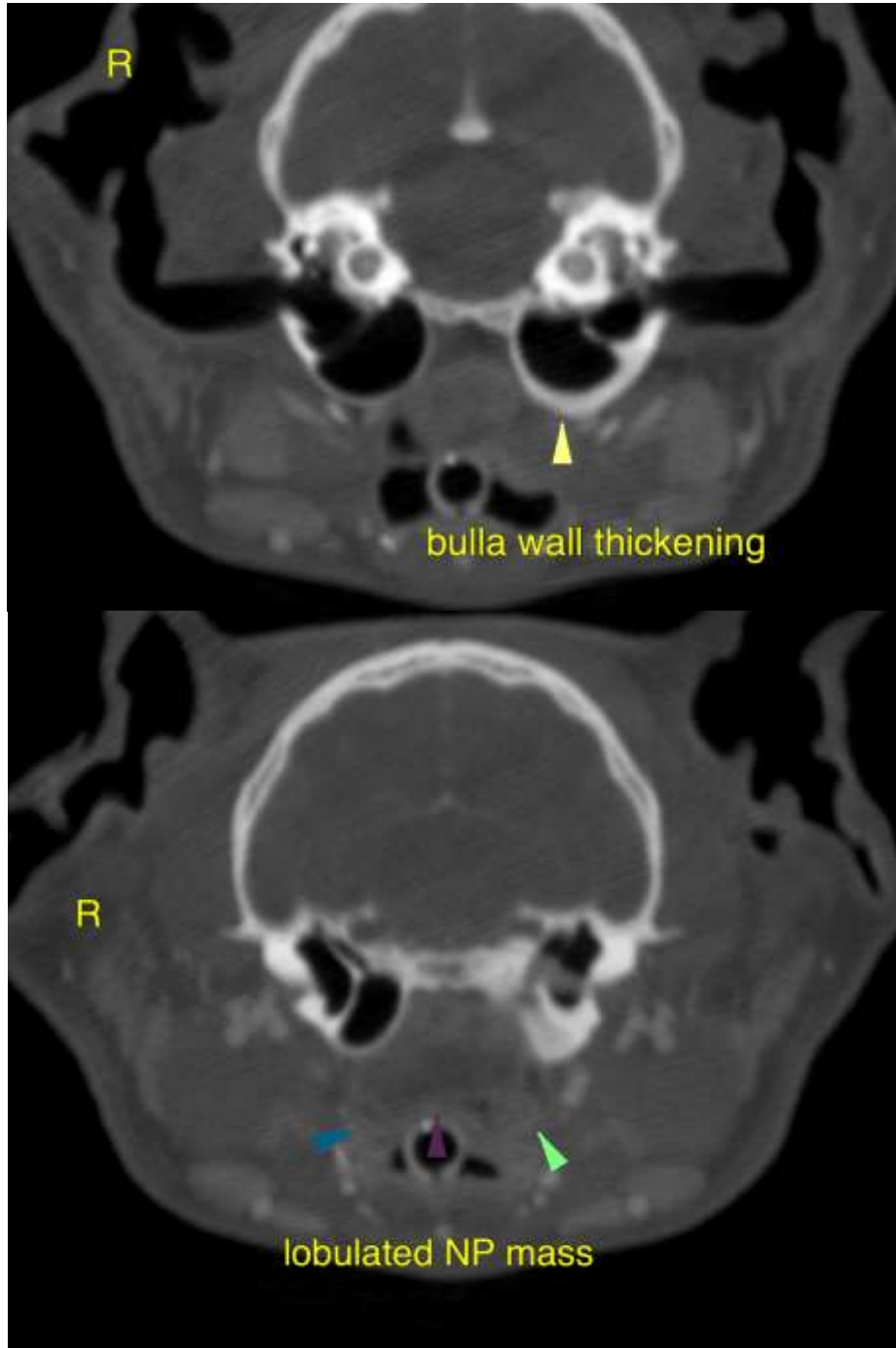
REFERRING VET

Dr. Juarez

INVOICE

9-22-21

DATE





PATIENT

Sugar Boy White

The information and recommendations provided are based on the images presented by the referring veterinarian. No evaluation can be communicated regarding pathology that was not visible in the image/video clips provided.

Thank you for this referral. If the clinical or image interpretation does not parallel your findings or if I can be of any further assistance please contact me.

SPECIES

Feline

Nele Eley, DVM, Dr. med. vet., DipECVDI
European Specialist in Veterinary Diagnostic Imaging, Cert. Radiology,
Senior lecturer University of Giessen, Germany, Veterinary Faculty, Department of Radiology
Nele.Eley@sonopath.com

BREED

DLH

SEX

NM

AGE

5 Years

INTERPRETED BY

Nele Eley, DVM
Dr. med. Vet. DipECVDI

HOSPITAL NAME

Paws and Claws
Urgent Care

REFERRING VET

Dr. Juarez

INVOICE

9-22-21

DATE