



PATIENT

Lilly Chutter

PRESENTING CLINICAL SIGNS

History of recurrent non-specific lower back pain with a tendency to laterally circumduct the hindlimbs and scuff the hind feet. Mild evidence of coxofemoral OA was found on radiographs, but no pain or restriction could be localized to the hip joints.

SPECIES

Canine

ULTRASONOGRAPHIC FINDINGS

Left & Right Iliopsoas Tendons

Mild irregular new bone formation is seen at the lesser trochanter in the left and right femur. The attachment of the psoas major tendons presents mild generalized thickening with an overall decrease in echogenicity with partial loss of echoarchitecture.

BREED

Golden Retriever

The musculotendinous junction and muscular portion of the psoas major present within normal limits in both hind limbs.

SEX

FS

Both coxofemoral joints reveal moderate anechoic effusion with moderate swelling of the synovium and a mild to moderate amount of circumferential femoral head osteophytes.

AGE

8 Years

ULTRASONOGRAPHIC DIAGNOSIS

- Mild chronic bilateral psoas major tendinopathy.
- Moderate bilateral coxofemoral joint effusion and synovialitis with mild signs of coxofemoral joint osteoarthritis.

INTERPRETED BY

Nele Eley, DVM
Dr. med. Vet. DipECVDI

INTERPRETATION OF THE FINDINGS & FURTHER RECOMMENDATIONS

The ultrasonographic findings confirm the suspicion of iliopsoas tendinopathy. Both psoas major tendons reveal signs of chronic insertional tendinopathy. This is likely to represent secondary or concomitant iliopsoas tendinopathy in conjunction with canine hip dysplasia and coxofemoral joint osteoarthritis.

HOSPITAL NAME

Points East West
Veterinary Services

REFERRING VET

David Lane

INVOICE

54187

DATE

9-20-22



PATIENT

Lilly Chutter

SPECIES

Canine

BREED

Golden Retriever

SEX

FS

AGE

8 Years

INTERPRETED BY

Nele Eley, DVM
Dr. med. Vet. DipECVDI

HOSPITAL NAME

Points East West
Veterinary Services

REFERRING VET

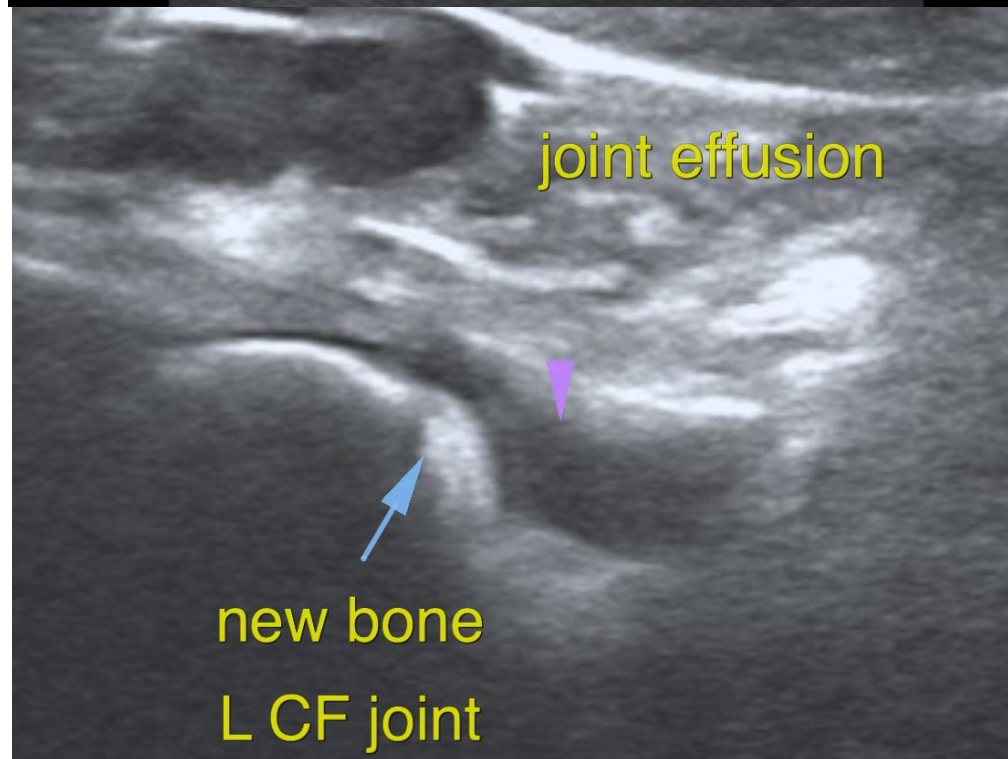
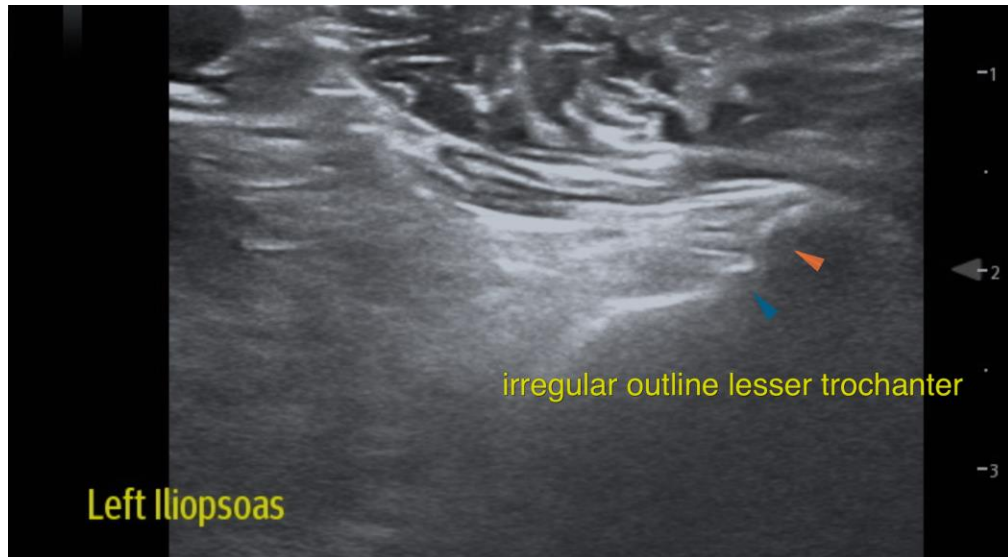
David Lane

INVOICE

54187

DATE

9-20-22





PATIENT

Lilly Chutter

SPECIES

Canine

BREED

Golden Retriever

SEX

FS

AGE

8 Years

INTERPRETED BY

Nele Eley, DVM
Dr. med. Vet. DipECVDI

HOSPITAL NAME

Points East West
Veterinary Services

REFERRING VET

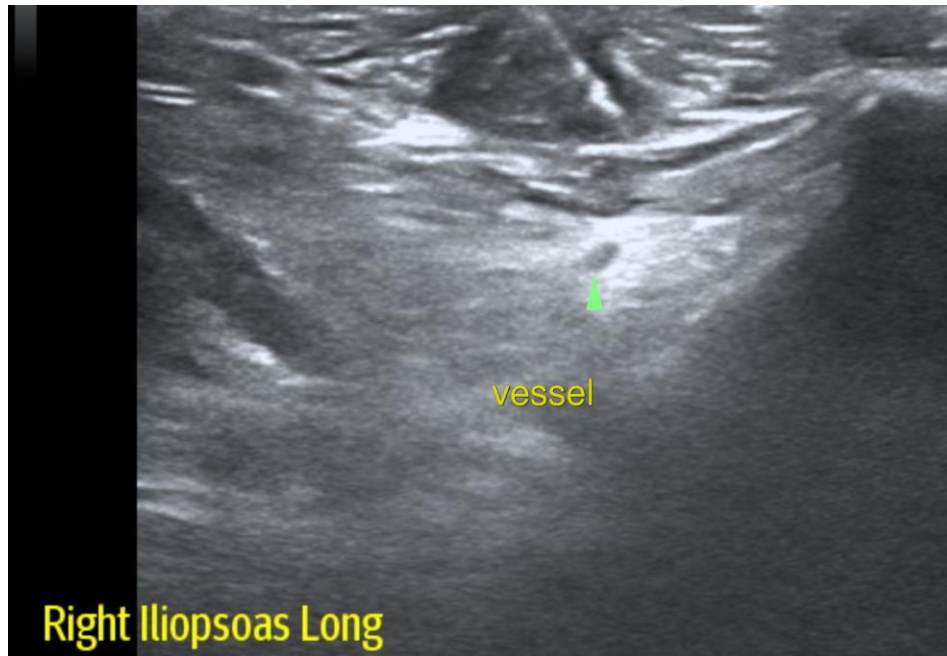
David Lane

INVOICE

54187

DATE

9-20-22



The information and recommendations provided are based on the images presented by the referring veterinarian/sonographer. No evaluation can be communicated regarding pathology that was not visible in the image/video clips provided.

Thank you for this referral. If the clinical or image interpretation does not parallel your findings or if I can be of any further assistance please contact me.

Nele Eley, DVM, Dr. med. vet., DipECVDI
European Specialist in Veterinary Diagnostic Imaging, Cert. Radiology,
Senior lecturer University of Giessen, Germany, Veterinary Faculty, Department of Radiology
Nele.Eley@sonopath.com