



PATIENT

Dixon Neterer

PRESENTING CLINICAL SIGNS

Dixon presents to SOVSC with swelling of her right eye and is currently being treated for autoimmune with prednisone 20mg twice daily. No other medications. Owner's report she was normal until 9/19, when the swelling started, not eating or drinking. Dixon was boarded for about 1 week, and was eating and drinking during that time. No pawing at her face and is increasing lethargic over the past 12 hours. Owner gave Benadryl 75mg 9/19 pm and has not given any additional meds since.

SPECIES

Canine

BREED

Labrador

COMPUTED TOMOGRAPHIC STUDY OF THE HEAD

Plain and post contrast studies available for review.

COMPUTED TOMOGRAPHIC FINDINGS

SEX

F

A large thick walled cavitory lesion with fluid filled contrast negative center and peripheral rim enhancement is seen in the right retrobulbar space. The cavitory lesion measures approximately 6.5 cm in height, 4.5 in length, and 3.0 cm in width. The lesion presents temporal and retromolar extension and is mostly situated medial to the coronoid process of the right mandible. Peripheral fat stranding is noted. There is no evidence of foreign material.

AGE

4 Years

The right zygomatic gland presents mild generalized enlargement. A small thin walled well delineated cavitory lesion with fluid filled center and peripheral rim enhancement is protruding beyond the right zygomatic arch. Mild peripheral soft tissue swelling is noted.

INTERPRETED BY

Nele Eley, DVM
Dr. med. Vet. DipECVDI

The right submandibular and retropharyngeal lymph nodes are moderately enlarged with mildly heterogeneous contrast enhancement.

COMPUTED TOMOGRAPHIC DIAGNOSIS

- Large right sided retrobulbar abscess with temporal and retromolar extension.
- Right sided medial retropharyngeal and submandibular lymphadenomegaly.
- Sialadenitis and small sialocele protruding beyond the right zygomatic arch.

HOSPITAL NAME

Southern Oregon
Veterinary Specialty
Center

INTERPRETATION OF THE FINDINGS & FURTHER RECOMMENDATIONS

The CT findings are compatible with a large retrobulbar abscess within the right orbital and retromolar soft tissues with extension into the temporal muscle. Foreign material is not seen however foreign matter related pathogenesis is considered likely and small pieces of organic foreign material may go unnoticed in CT. The foreign material may also have migrated.

REFERRING VET

Kimberly Winters

The lymph node changes are compatible with reactive or suppurative lymphadenitis.

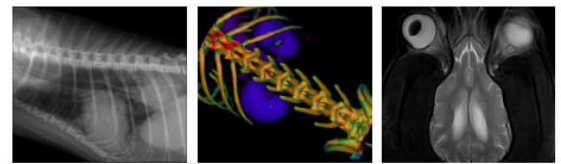
INVOICE

54178

Note the presence of a small sialocele of the right zygomatic gland with prolapse beyond the zygomatic arch and concomitant sialadenitis.

DATE

9-20-22



PATIENT

Dixon Neterer

SPECIES

Canine

BREED

Labrador

SEX

F

AGE

4 Years

INTERPRETED BY

Nele Eley, DVM
Dr. med. Vet. DipECVDI

HOSPITAL NAME

Southern Oregon
Veterinary Specialty
Center

REFERRING VET

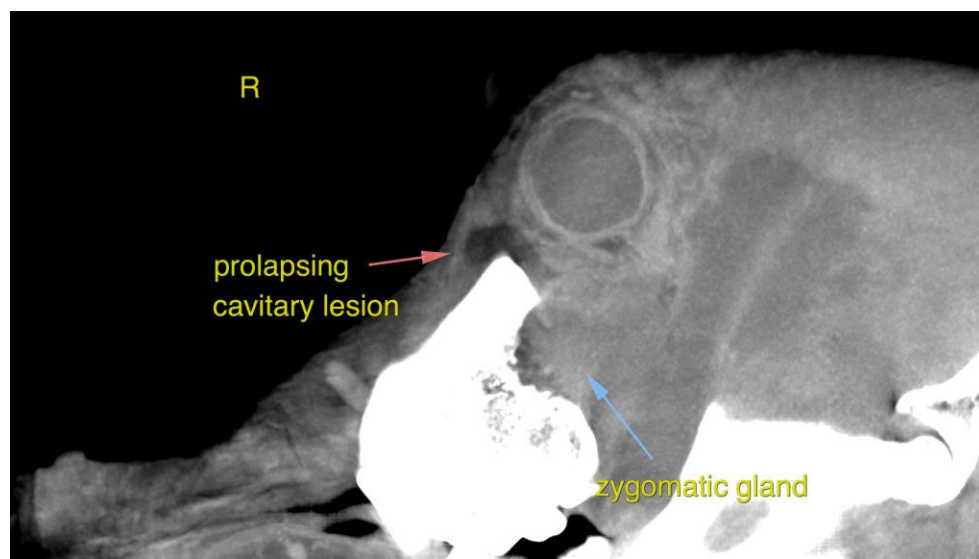
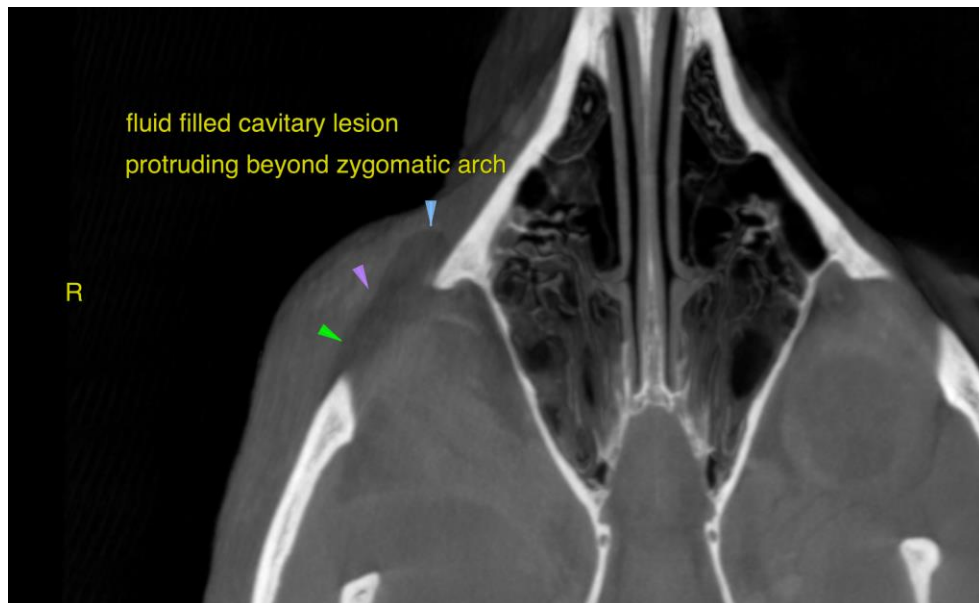
Kimberly Winters

INVOICE

54178

DATE

9-20-22





PATIENT

Dixon Neterer

SPECIES

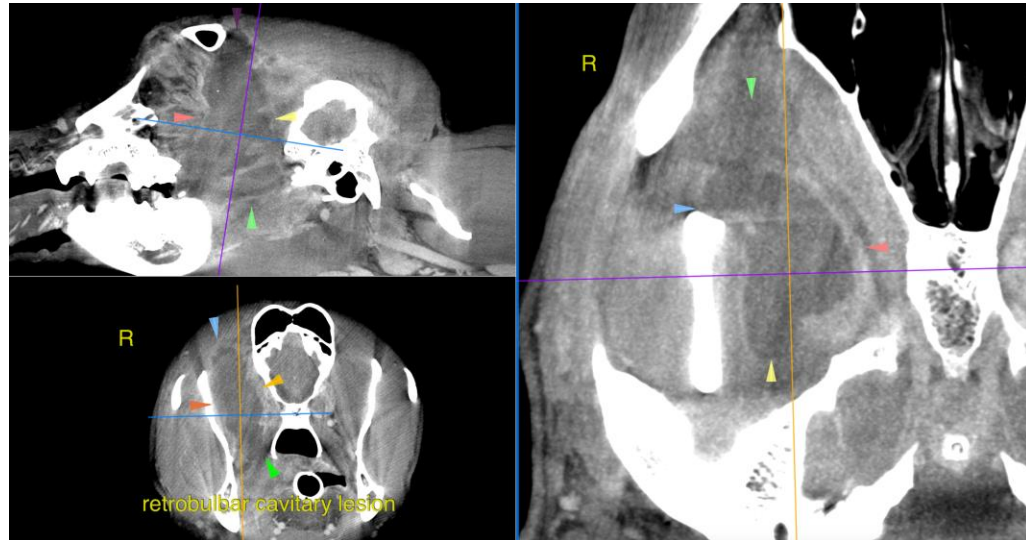
Canine

BREED

Labrador

SEX

F



AGE

4 Years

The information and recommendations provided are based on the images presented by the referring veterinarian/sonographer. No evaluation can be communicated regarding pathology that was not visible in the image/video clips provided.

INTERPRETED BY

Nele Eley, DVM
Dr. med. Vet. DipECVDI

Thank you for this referral. If the clinical or image interpretation does not parallel your findings or if I can be of any further assistance please contact me.

Nele Eley, DVM, Dr. med. vet., DipECVDI
European Specialist in Veterinary Diagnostic Imaging, Cert. Radiology,
Senior lecturer University of Giessen, Germany, Veterinary Faculty, Department of Radiology
Nele.Eley@sonopath.com

HOSPITAL NAME

Southern Oregon
Veterinary Specialty
Center

REFERRING VET

Kimberly Winters

INVOICE

54178

DATE

9-20-22