



PATIENT

Lucy Poustovar

PRESENTING CLINICAL SIGNS

Diarrhea on and off for more than 3 weeks, has lost some weight
Abnormal PE/Chem/CBC/UA Results: Pain response when pressure applied on mid abdomen
cPL is normal, WBC, Neu# is low, LYM% is high, and Platelet is decreased.

SPECIES

Canine

RADIOGRAPHIC STUDY OF THE ABDOMEN

Right/left lateral and ventrodorsal views of the abdomen totaling 4 images available for review.

BREED

German Shepherd

RADIOGRAPHIC FINDINGS

The patient is in thin body condition.

The abdominal serosal detail appears to be reduced in the mid abdomen which, however, is likely due to crowding of the intestines.

SEX

Female

The stomach presents mild aerophagia.

Mild generalized dilation of the small intestine with gas is seen. There is no evidence of segmental dilation, plication, or radiopaque foreign material.

AGE

7 Years

The colon contains a large amount of fecal matter.

INTERPRETED BY

Nele Eley, DVM
Dr. med. Vet. DipECVDI

RADIOGRAPHIC DIAGNOSIS

- Gastrointestinal maldigestion pattern.

INTERPRETATION OF THE FINDINGS & FURTHER RECOMMENDATIONS

The radiographic study reveals a gastrointestinal maldigestion pattern which is an unspecific finding that may be associated with functional ileus, gastroenteropathy, dietary indiscretion, pancreatopathy, hepatopathy, and systemic disease. Further definition by means of abdominal ultrasound could be considered.

HOSPITAL NAME

St. Catherine's Animal
Hospital

REFERRING VET

Dr. Boctor

INVOICE

54111

DATE

9-19-22



PATIENT

Lucy Poustovar

SPECIES

Canine

BREED

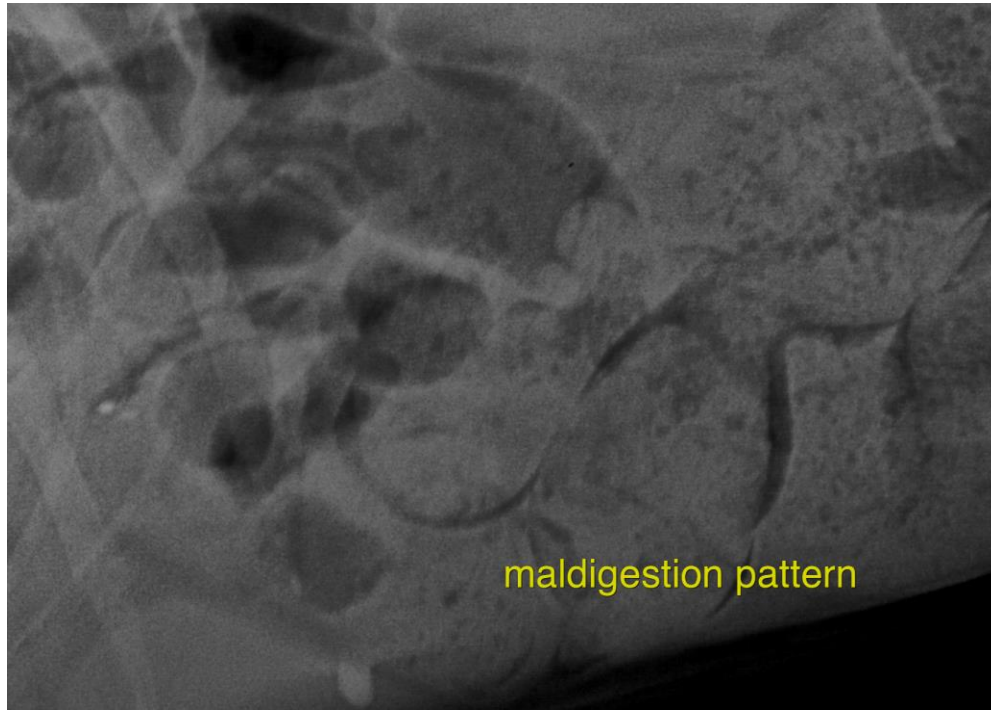
German Shepherd

SEX

Female

AGE

7 Years



INTERPRETED BY

Nele Eley, DVM
Dr. med. Vet. DipECVDI

The information and recommendations provided are based on the images presented by the referring veterinarian/sonographer. No evaluation can be communicated regarding pathology that was not visible in the image/video clips provided.

Thank you for this referral. If the clinical or image interpretation does not parallel your findings or if I can be of any further assistance please contact me.

HOSPITAL NAME

St. Catherine's Animal
Hospital

Nele Eley, DVM, Dr. med. vet., DipECVDI
European Specialist in Veterinary Diagnostic Imaging, Cert. Radiology,
Senior lecturer University of Giessen, Germany, Veterinary Faculty, Department of Radiology
Nele.Eley@sonopath.com

REFERRING VET

Dr. Boctor

INVOICE

54111

DATE

9-19-22