



PATIENT PRESENTING CLINICAL SIGNS

Kelly Cotton Repeat radiographs of thoracic cavity to recheck on chronic active lower airway disease. P is on Prednisone, cough has improved, only coughing about 2 times a day.

SPECIES RADIOGRAPHIC STUDY OF THE THORAX

Ca Right/left lateral and ventrodorsal views of the thorax totaling 3 images available for review. Compared with prior study dated 8-31-22.

BREED RADIOGRAPHIC FINDINGS

Mixed Reduced peribronchial markings and infiltrate are seen in the recent study when compared with the prior images dated 8-31. A residual generalized bronchial lung pattern with thin walled appearance is noted.

SEX RADIOGRAPHIC DIAGNOSIS

Spayed Female

- Regression of the peribronchial bronchointerstitial infiltrate.

INTERPRETATION OF THE FINDINGS & FURTHER RECOMMENDATIONS

9 Years

The radiographic study reveals significant reduction of the peribronchial increase in interstitial opacity which is accentuated in the caudal and dorsal aspect of the lung. The thin walled increase in the visibility of the bronchial markings is generalized, stationary, and presumed to be irreversible which, however, is not necessarily an expression of active inflammation or infection and not necessarily of clinical significance.

INTERPRETED BY

Nele Eley, DVM
Dr. med. Vet. DipECVCI

HOSPITAL NAME

The Pet Hospital of
Stratford

REFERRING VET

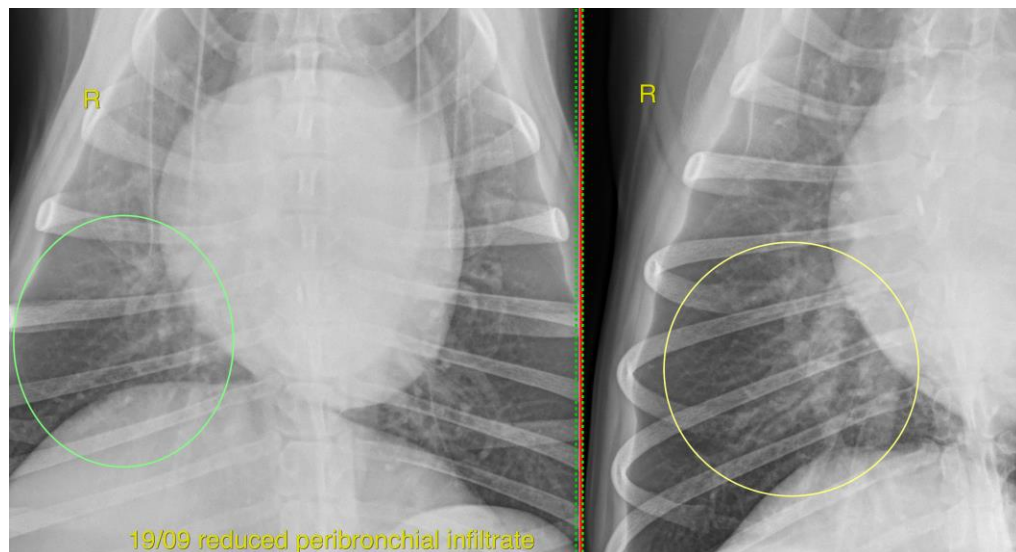
Dr. Claudia Giuliani

INVOICE

54115

DATE

9-19-22





PATIENT

Kelly Cotton

The information and recommendations provided are based on the images presented by the referring veterinarian/sonographer. No evaluation can be communicated regarding pathology that was not visible in the image/video clips provided.

Thank you for this referral. If the clinical or image interpretation does not parallel your findings or if I can be of any further assistance please contact me.

SPECIES

Ca

Nele Eley, DVM, Dr. med. vet., DipECVDI
European Specialist in Veterinary Diagnostic Imaging, Cert. Radiology,
Senior lecturer University of Giessen, Germany, Veterinary Faculty, Department of Radiology
Nele.Eley@sonopath.com

BREED

Mixed

SEX

Spayed Female

AGE

9 Years

INTERPRETED BY

Nele Eley, DVM
Dr. med. Vet. DipECVDI

HOSPITAL NAME

The Pet Hospital of
Stratford

REFERRING VET

Dr. Claudia Giuliani

INVOICE

54115

DATE

9-19-22