



PATIENT PRESENTING CLINICAL SIGNS

Baxter Tamsin coughing fits resulting in syncope multiple lipomas removed
 Abnormal PE/Chem/CBC/UA Results: moderate elevation ALKP/BUN - creatinine normal
 FNA of right thoracic mass - fat globules only

SPECIES COMPUTED TOMOGRAPHIC STUDY OF THE THORAX & ABDOMEN

Canine Plain and post contrast studies in soft tissue, bone, and lung windows available for review.

BREED COMPUTED TOMOGRAPHIC FINDINGS

Schnauzer **Abdomen**

Moderate generalized hepatomegaly with slightly rounded lobar margins is seen. The parenchymal attenuation and enhancement are uniform.

SEX Multiple epigastric lymphadenomegaly involving the gastric and portal lymph nodes is seen. the lymph nodes measure up to 2.5 cm in diameter are rounded and hypoattenuating.

AGE The spleen presents within the expected limits.

13 The kidneys and adrenal glands present within expected limits as well.

The stomach is postprandial. No structural abnormality of the gastrointestinal tract is seen.

INTERPRETED BY Note the presence of gastroesophageal reflux.

Nele Eley, DVM
 Dr. med. Vet. DipECVDI

Thorax

The patient is obese.

HOSPITAL NAME Multiple thoracic and abdominal wall lipomas are seen. An intrathoracic lipoma is seen in the ventral half of the right pleural cavity.

Advanced Veterinary
 Imaging

The degree of pulmonary inflation is poor. A moderate generalized increase in interstitial pulmonary attenuation is seen.

REFERRING VET The mediastinal lymph nodes present within normal limits.

Eamon The main pulmonary artery may be enlarged.

INVOICE Mild dorsal flattening of the tracheal membrane is noted.

54096 **COMPUTED TOMOGRAPHIC DIAGNOSIS**

- DATE**
- Diffuse interstitial lung disease.
 - Multiple epigastric lymphadenomegaly.
 - Hepatomegaly.
 - Obesity.

9-18-22



PATIENT

Baxter Tamsin

- Multiple body wall lipomas and right pleural cavity lipoma.

INTERPRETATION OF THE FINDINGS & FURTHER RECOMMENDATIONS

SPECIES

Canine

The CT study reveals diffuse interstitial lung disease. Differential diagnosis includes pulmonic fibrosis, interstitial pneumonia, and diffuse neoplastic infiltrate with round cells. Acute respiratory distress and other noncardiogenic pulmonary edema are potential but less likely differential diagnoses. The potential presence of pulmonic hypertension and cor pulmonale should be considered.

BREED

Schnauzer

Multiple epigastric lymphadenomegaly is suggestive for a neoplastic infiltrate based on the pattern of enlargement including round cell neoplasia, metastases of another undetermined primary tumor, or other. Ultrasound guided fine needle aspiration is recommended for further definition.

SEX

MN

Ultrasound guided fine needle aspiration of the pulmonary interstitium could be considered as well.

A cardiac echo could be considered to screen for pulmonary hypertension.

AGE

13

Differential diagnosis for the hepatomegaly includes vacuolar, endocrine, metabolic, diffuse neoplastic, and diffuse inflammatory/infectious disease. Consider fine needle aspiration or biopsy for further definition.

INTERPRETED BY

Nele Eley, DVM
Dr. med. Vet. DipECVDI

HOSPITAL NAME

Advanced Veterinary
Imaging

REFERRING VET

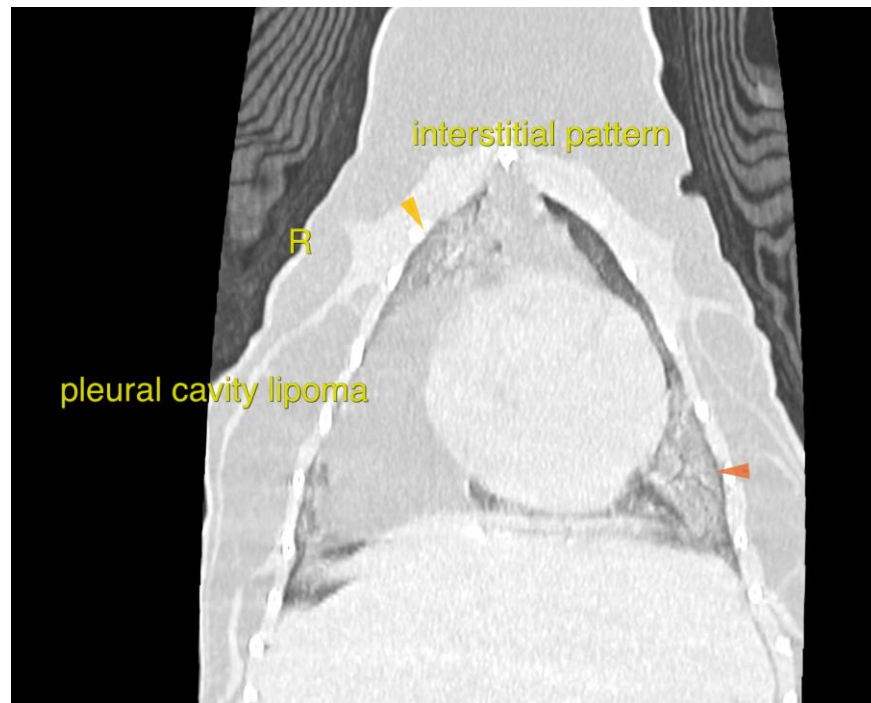
Eamon

INVOICE

54096

DATE

9-18-22





PATIENT

Baxter Tamsin

SPECIES

Canine

BREED

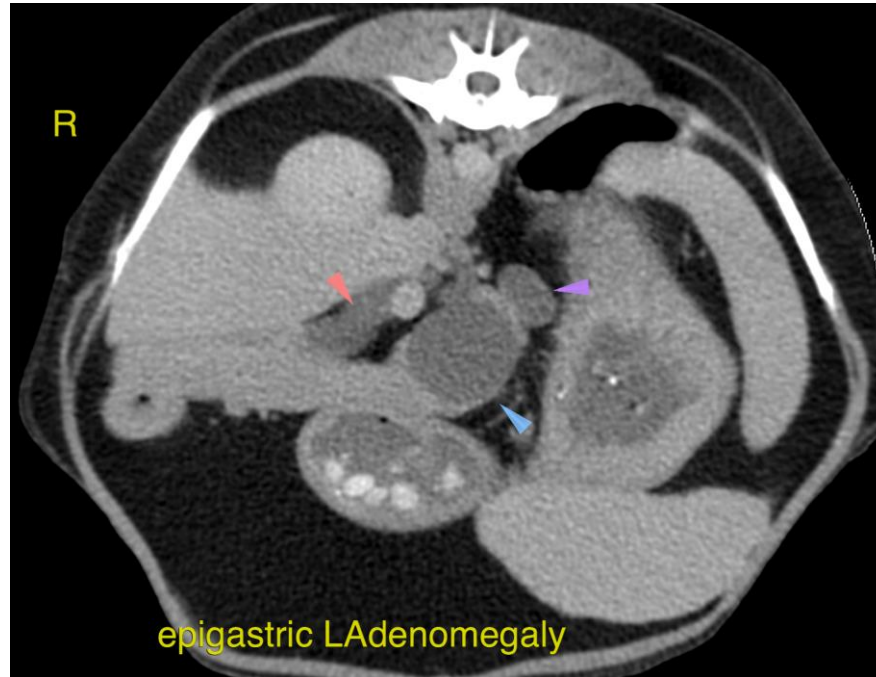
Schnauzer

SEX

MN

AGE

13



INTERPRETED BY

Nele Eley, DVM
Dr. med. Vet. DipECVDI

The information and recommendations provided are based on the images presented by the referring veterinarian/sonographer. No evaluation can be communicated regarding pathology that was not visible in the image/video clips provided.

Thank you for this referral. If the clinical or image interpretation does not parallel your findings or if I can be of any further assistance please contact me.

HOSPITAL NAME

Advanced Veterinary
Imaging

Nele Eley, DVM, Dr. med. vet., DipECVDI
European Specialist in Veterinary Diagnostic Imaging, Cert. Radiology,
Senior lecturer University of Giessen, Germany, Veterinary Faculty, Department of Radiology
Nele.Eley@sonopath.com

REFERRING VET

Eamon

INVOICE

54096

DATE

9-18-22