



PATIENT PRESENTING CLINICAL SIGNS

PATIENT Dookie Geitl Presented for second opinion regarding ongoing coughing. First started in January this year. At that time, their previous vet did not have radiographs available so prescribed a course of antibiotics. After no response, referred to another vet for radiographs. Radiographs sent to RadTerra and report showed "...diffuse bronchial pattern with an interstitial component..." No heart murmur auscultated. Seen at VEC south in July due to a seizure that lasted about 4 minutes.

SPECIES Canine Blood work at the time was unremarkable. Started on Levetiracetam 250mg PO q8h. No seizures since. Radiographs were retaken here as crackles were auscultated in his lungs, more markedly on right side of chest. Mild sedation with Butorphanol given prior to taking radiographs. (DV, RL and LL). No heart murmurs or arrhythmias noted. No fever. MM pink and CRT <1. Other dog at home has started coughing over the past 48 hours and there is a dog in the building they live in that has kennel cough. Started both dogs on doxycycline and also gave an injection of Furosemide to Dookie prior to going home. Recommended sending radiographs out but O wanted to wait 24-48 hours to see any response to treatment. Coughing is still bad at 48h despite antibiotics and Hycodan. O consented to radiographs being sent out today and will start Terbutaline PO.

BREED Pug

SEX NM

RADIOGRAPHIC STUDY OF THE THORAX

Right/left lateral and ventrodorsal views totaling 3 images available for review.

AGE RADIOGRAPHIC FINDINGS

12 Years Mild generalized osteopenia is seen and considered within age related normal limits.

INTERPRETED BY There is mild elbow osteoarthritis and mild bilateral shoulder osteoarthritis.

Nele Eley, DVM
Dr. med. Vet. DipECVDI
Mild redundancy of the dorsal tracheal ligament is seen in the cervical trachea. Mild intrathoracic tracheal collapse of the precardinal trachea is seen on the right lateral view. This appears to be less pronounced on the left lateral view.

HOSPITAL NAME The degree of pulmonary inflation is fair. A moderate generalized bronchial lung pattern with occasional peribronchial cuffing and peribronchial interstitial infiltrates is seen.

Balmy Beach Pet Hospital
The radiographic presentation of the cardiac silhouette is considered within normal limits. No specific chamber enlargement is seen. The vertebral heart score is 10.2.

REFERRING VET The visible abdominal structures present within normal limits.

Dr. Yogo Mild gastric aerophagia is noted.

RADIOGRAPHIC DIAGNOSIS

- INVOICE**
- 47460
- Moderate chronic active lower airway pattern.
 - Mild dynamic intrathoracic tracheal collapse.
 - No radiographic evidence of cardiovascular pathology.
 - Shoulder and elbow osteoarthritis - unrelated to the reason of clinical presentation.
 - Aerophagia.
- DATE**

9-17-21



PATIENT

Dookie Geitl

INTERPRETATION OF THE FINDINGS & FURTHER RECOMMENDATIONS

The radiographic study confirms presence of chronic active lower airway disease. Consider eosinophilic bronchopneumopathy a potential as well as infectious bronchitis such as viral, bacterial, and less likely parasitic or protozoal. With the pertinent history, chronic eosinophilic bronchopneumopathy should be considered as well as recent superinfection.

SPECIES

Canine

The intrathoracic tracheal collapse may well contribute to the clinical signs as well. Consider upper and lower airway endoscopy with airway sampling for a more definitive diagnosis.

BREED

Pug

SEX

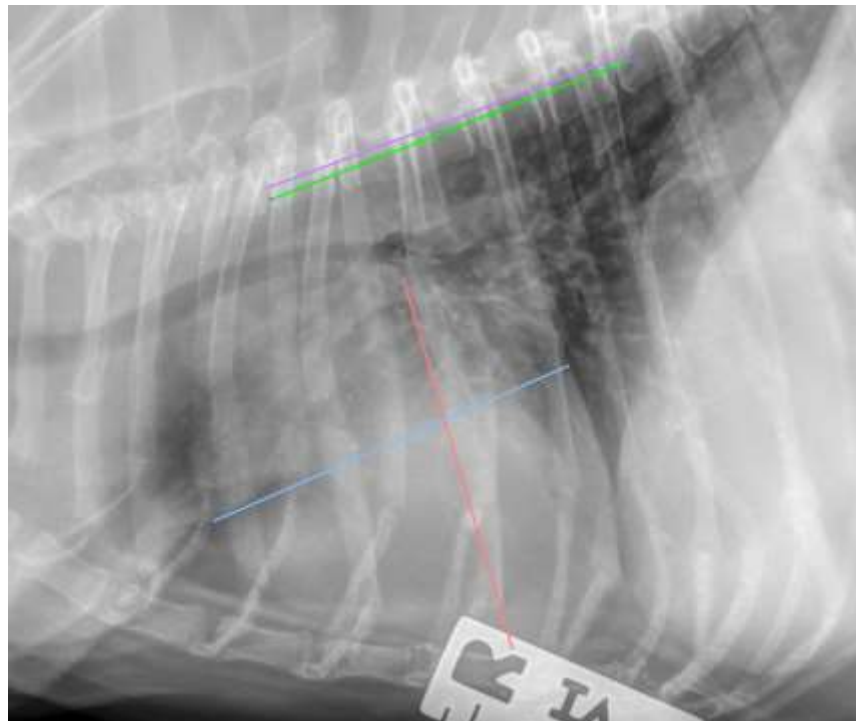
NM

AGE

12 Years

INTERPRETED BY

Nele Eley, DVM
Dr. med. Vet. DipECVDI



HOSPITAL NAME

Balmy Beach Pet
Hospital

REFERRING VET

Dr. Yogo

The information and recommendations provided are based on the images presented by the referring veterinarian. No evaluation can be communicated regarding pathology that was not visible in the image/video clips provided.

INVOICE

47460

Thank you for this referral. If the clinical or image interpretation does not parallel your findings or if I can be of any further assistance please contact me.

DATE

9-17-21

Nele Eley, DVM, Dr. med. vet., DipECVDI
European Specialist in Veterinary Diagnostic Imaging, Cert. Radiology,
Senior lecturer University of Giessen, Germany, Veterinary Faculty, Department of Radiology
Nele.Eley@sonopath.com