



PATIENT

Matzah Woloshin

PRESENTING CLINICAL SIGNS

Patient presented for yowling at home, painful on upper lumbar palpation. Owner states pet has history of kidney disease but no records

SPECIES

Feline

RADIOGRAPHIC STUDY OF THE THORACIC & LUMBAR SPINE

Lateral views of the thoracic and lumbar spine and dorsoventral view of the lumbar spine totaling 3 images available for review.

BREED

Calico

RADIOGRAPHIC FINDINGS

General anatomy, number, and alignment of the thoracic and lumbar vertebrae present within age related normal limits.

SEX

FS

The intervertebral disc space width L5/6 is mildly reduced with early osseous remodeling of the neighboring vertebral end plates.

No evidence of aggressive bone lesions or traumatic osseous injury is seen throughout the thoracic and lumbar spine.

AGE

16 Years

The urinary bladder is moderately distended.

Visible thoracic and abdominal structures present within normal limits.

INTERPRETED BY

Nele Eley, DVM
Dr. med. Vet. DipECVDI

RADIOGRAPHIC DIAGNOSIS

- Presumably chronic intervertebral disc disease within the caudal lumbar spine at L5/6 - otherwise, normal radiographic presentation of the thoracolumbar spine.

HOSPITAL NAME

Boca Park Animal
Hospital

INTERPRETATION OF THE FINDINGS & FURTHER RECOMMENDATIONS

No definitive cause of the patient's clinical signs can be identified in the radiographic study of the thoracic and lumbar spine. The changes associated with the intervertebral disc space L5/6 are most likely due to intervertebral disc disease. The vertebral end plate remodeling indicates chronicity; however, acute on chronic disease cannot be ruled out and differential diagnosis includes disc associated as well as non-disc associated myelopathies as well as hyperesthesia syndrome, soft tissue injury, or inflammation. Cross sectional imaging (ideally MRI or CT myelogram) could be considered for further definition depending on the severity and development of the clinical signs.

REFERRING VET

Dr. Corinna Gorgon

INVOICE

47428

DATE

9-16-21



PATIENT

Matzah Woloshin

SPECIES

Feline

BREED

Calico

SEX

FS

AGE

16 Years

INTERPRETED BY

Nele Eley, DVM
Dr. med. Vet. DipECVDI

HOSPITAL NAME

Boca Park Animal
Hospital

REFERRING VET

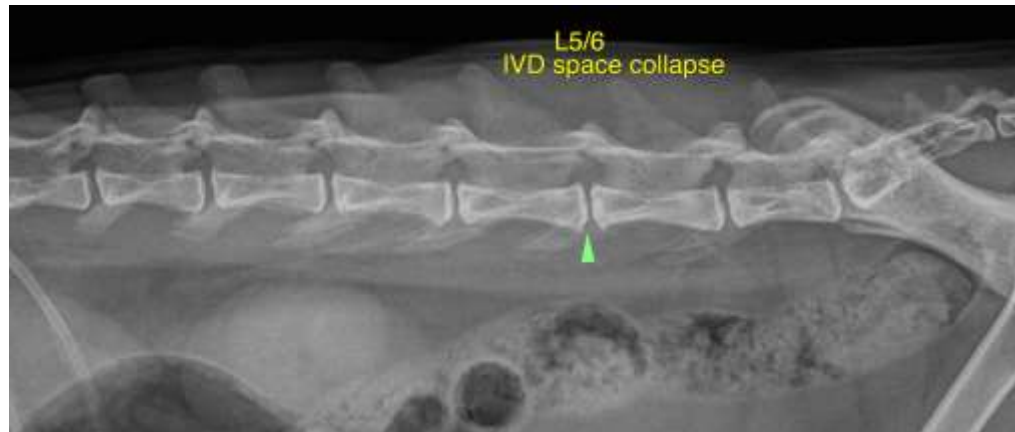
Dr. Corinna Gorgon

INVOICE

47428

DATE

9-16-21



The information and recommendations provided are based on the images presented by the referring veterinarian. No evaluation can be communicated regarding pathology that was not visible in the image/video clips provided.

Thank you for this referral. If the clinical or image interpretation does not parallel your findings or if I can be of any further assistance please contact me.

Nele Eley, DVM, Dr. med. vet., DipECVDI
European Specialist in Veterinary Diagnostic Imaging, Cert. Radiology,
Senior lecturer University of Giessen, Germany, Veterinary Faculty, Department of Radiology
Nele.Eley@sonopath.com