



**PATIENT**

Georgie Massaro

**PRESENTING CLINICAL SIGNS**

Not eating, possible mandibular fracture noted on radiographs.

**SPECIES**

Lagamorph

**COMPUTED TOMOGRAPHIC STUDY OF THE HEAD**

Plain and post contrast studies available for review.

**BREED**

Rabbit

**COMPUTED TOMOGRAPHIC FINDINGS**

The dentition is complete. Mild elongation of the Triadans 102 and 202 is seen. The overall length and conformation of the tooth crowns are considered within normal limits. Only mild retrograde elongation of the premolar and molar tooth roots is seen. Overall, there is no evidence of a mandibular or maxillary fracture. No evidence of tooth root abscessation is seen.

**SEX**

Male Neutered

The temporomandibular joints present within normal limits.

The left submandibular lymph node presents moderate symmetric enlargement when compared with the right side.

**AGE**

5 Years

**COMPUTED TOMOGRAPHIC DIAGNOSIS**

- Minimal elongation of the tooth crowns 102 and 202, and minimal elongation of the premolar and molar tooth roots - otherwise, normal dentition and no evidence of traumatic or pathologic fracture.
- Left submandibular lymphadenomegaly.

**INTERPRETED BY**

Nele Eley, DVM  
Dr. med. Vet. DipECVDI

**INTERPRETATION OF THE FINDINGS & FURTHER RECOMMENDATIONS**

The CT study does not confirm the suspicion of mandibular fracture. The osseous structures of the skull are within normal limits. The overall presentation of the dentition is within normal limits despite the mild elongation of the tooth crowns 102 and 202 as well as mild retrograde elongation of tooth roots. The overall wear of the occlusal surfaces appears to be within normal limits. No evidence of tooth root abscessation is seen. The temporomandibular joints present within normal limits.

**HOSPITAL NAME**

Mobile Pet Imaging

**REFERRING VET**

Meaux

Differential diagnosis for the left submandibular lymphadenomegaly includes lymphadenitis, lymph node abscessation and infiltrative disease such as lymphoma. Consider fine needle aspiration for further definition.

**INVOICE**

47408

**DATE**

9-16-21



**PATIENT**

Georgie Massaro

**SPECIES**

Lagamorph

**BREED**

Rabbit

**SEX**

Male Neutered

**AGE**

5 Years

**INTERPRETED BY**

Nele Eley, DVM  
Dr. med. Vet. DipECVDI

**HOSPITAL NAME**

Mobile Pet Imaging

**REFERRING VET**

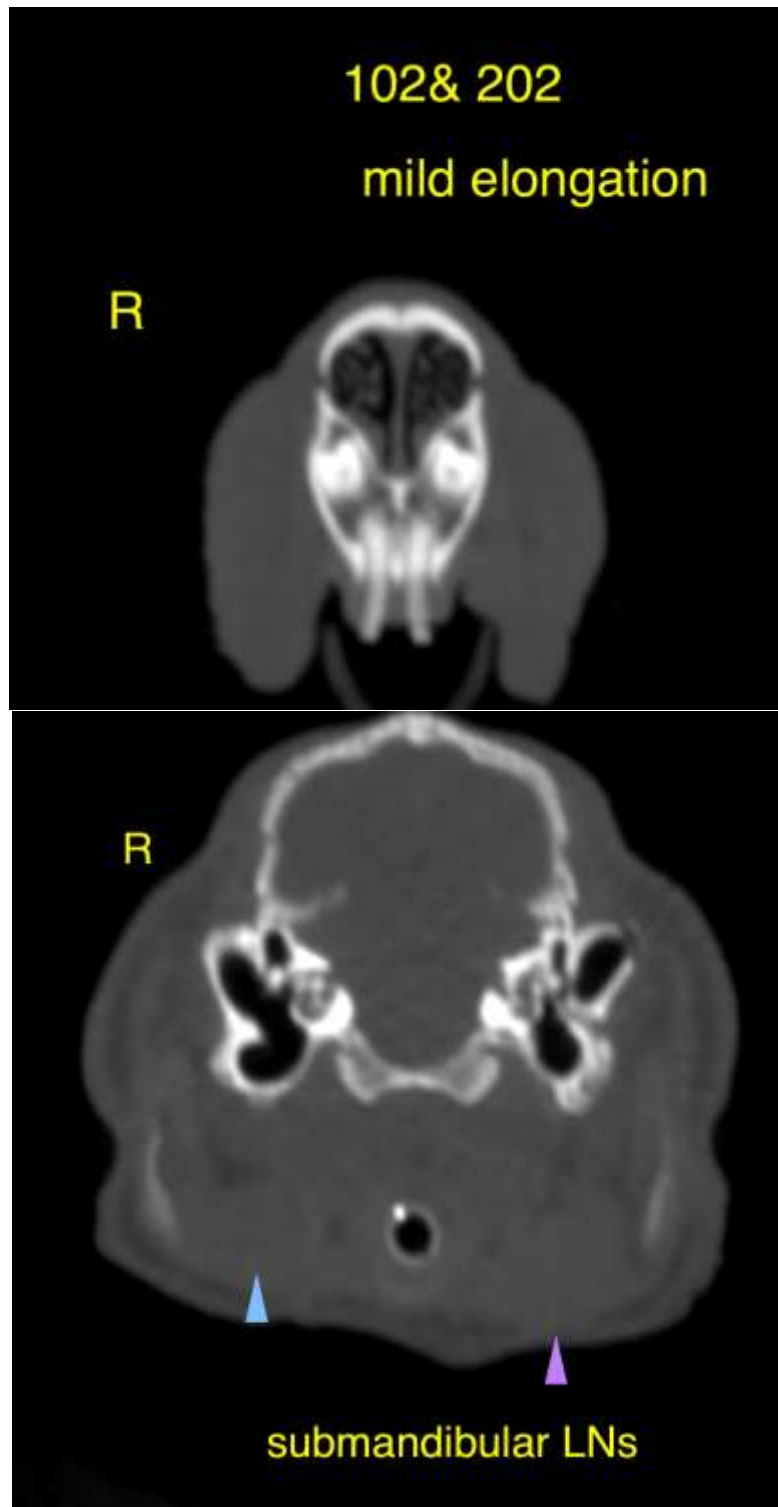
Meaux

**INVOICE**

47408

**DATE**

9-16-21





**PATIENT**

Georgie Massaro

The information and recommendations provided are based on the images presented by the referring veterinarian. No evaluation can be communicated regarding pathology that was not visible in the image/video clips provided.

**SPECIES**

Lagomorph

Thank you for this referral. If the clinical or image interpretation does not parallel your findings or if I can be of any further assistance please contact me.

**BREED**

Rabbit

**Nele Eley**, DVM, Dr. med. vet., DipECVDI  
European Specialist in Veterinary Diagnostic Imaging, Cert. Radiology,  
Senior lecturer University of Giessen, Germany, Veterinary Faculty, Department of Radiology  
Nele.Eley@sonopath.com

**SEX**

Male Neutered

**AGE**

5 Years

**INTERPRETED BY**

Nele Eley, DVM  
Dr. med. Vet. DipECVDI

**HOSPITAL NAME**

Mobile Pet Imaging

**REFERRING VET**

Meaux

**INVOICE**

47408

**DATE**

9-16-21