



**PATIENT PRESENTING CLINICAL SIGNS**

**PATIENT** Cane Barbosa  
**SPECIES** Canine  
**BREED** Doberman Pinscher

Patient presented on 9/7 for walking stiffly and losing confidence in his walking for the prior 2 weeks. Progression downward was rapid. It started with him not wanting to go down stairs and now is having accidents in house and struggles to stand in general. Limbs are very stiff and feet knuckle. Cries as if in pain for most of the day. Cosequin, Omega 3s, CBD oil have not helped. Ataxic x 4, poor CP in the pelvic limbs and left thoracic limb. Very hard to accurately assess the neurological status of the thoracic limbs due to his size and constant stumbling. Sedated radiographs of the vertebral column revealed IVD space narrowing and spondylosis deformans at C6 - 7, mild enlargement of the caudal cervical articular process joints (worse at C5 - 6), mild dorsal tipping of C7, multifocal, and variable but mild osteophytosis of the TL articular process joints.

Abnormal PE/Chem/CBC/UA Results: CBC/CMP/T4/UA - WNL/NSF

**MAGNETIC RESONANCE IMAGING STUDY OF THE CERVICAL, THORACIC, & LUMBAR SPINE**

**SEX** MN  
T2-weighted, myelo/HASTE, STIR, T1-weighted, plain and post-contrast sequences available for review.

**MAGNETIC RESONANCE IMAGING FINDINGS**

**AGE** 6 Years, 3 Months

Reduced nucleus pulposus signal, reduced intervertebral disc space width, and moderate intervertebral disc protrusion is seen within the deep cervical spine at C5/6 and C6/7. Significant vertebral end plate remodeling with spondylosis deformans is present at C6/7. The cranial vertebral end plates of C6 and C7 present dorsal tipping with mild vertebral canal step formation and stenosis accentuating C6/7. There is mild dorsal deviation of the spinal cord level with the intervertebral disc protrusions at C5/6 and C6/7. No evidence of signal alteration of the spinal cord is noted at C5/6. Marked focal hyperintensity of the spinal cord with reduced spinal cord diameter is noted in all fluid sensitive sequences at C6/7.

**INTERPRETED BY**

Nele Eley, DVM  
Dr. med. Vet. DipECVDI

**HOSPITAL NAME**

South Bay Animal  
Hospital

Varying degrees of degenerative disc disease are noted throughout the entire spine.

There is multifocal mild to moderate degenerative spondyloarthropathy within the thoracic spine accentuating T9 through T12.

Mild non-compressive intervertebral disc protrusions are present at T12/13, T13/L1, and L1/2.

**REFERRING VET**

Ravinder Atwal, DVM,  
CCRP

The lumbosacral junction presents within normal limits.

Occasional hypointense splenic nodules are seen on T2-weighted sequences.

**MAGNETIC RESONANCE IMAGING DIAGNOSIS**

**INVOICE**

47449

- Chronic disc associated caudocervical spondylomyelopathy with intervertebral disc protrusion C5/6 and C6/7 and presumed spinal cord gliosis at C6/7.
- Mild non-compressive intervertebral disc protrusions T12 through L2 - unlikely to be of clinical significance.
- Splenic nodules compatible with benign nodular hyperplasia.

**DATE**

9-16-21



**PATIENT**

Cane Barbosa

**SPECIES**

Canine

**BREED**

Doberman Pinscher

**SEX**

MN

**AGE**

6 Years, 3 Months

**INTERPRETED BY**

Nele Eley, DVM  
Dr. med. Vet. DipECVDI

**HOSPITAL NAME**

South Bay Animal  
Hospital

**REFERRING VET**

Ravinder Atwal, DVM,  
CCRP

**INVOICE**

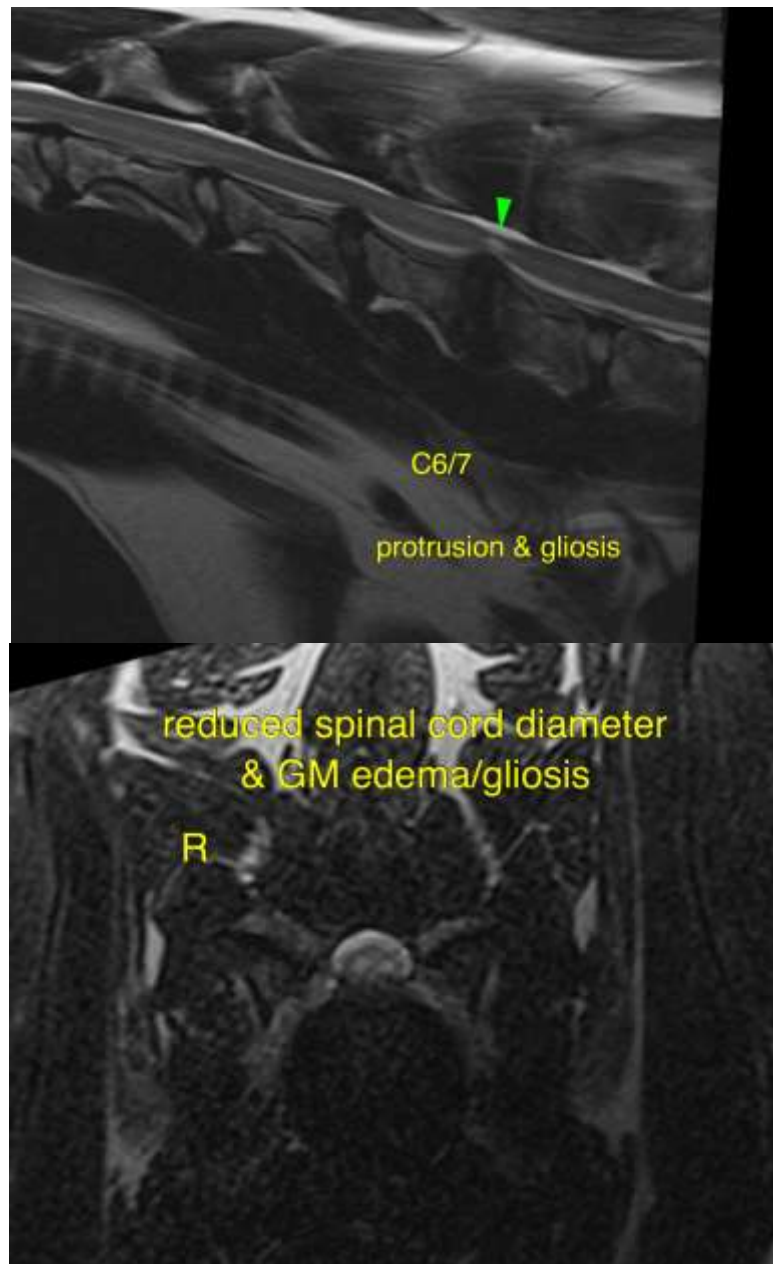
47449

**DATE**

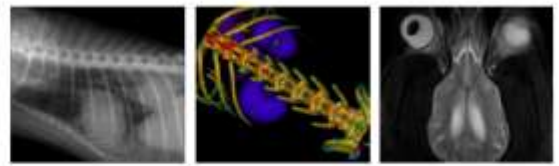
9-16-21

**INTERPRETATION OF THE FINDINGS & FURTHER RECOMMENDATIONS**

The MRI study confirms presence of caudocervical spondylomyelopathy with presumed spinal cord gliosis due to chronic compression at C6/7. The protrusion may be exacerbated during extension. Myelographic techniques could be considered, especially should this be a candidate for surgery, in order to determine dynamic component of the compression and to verify as to whether this is a traction responsive hernia.



The information and recommendations provided are based on the images presented by the



**PATIENT**

Cane Barbosa

referring veterinarian. No evaluation can be communicated regarding pathology that was not visible in the image/video clips provided.

Thank you for this referral. If the clinical or image interpretation does not parallel your findings or if I can be of any further assistance please contact me.

**SPECIES**

Canine

**Nele Eley**, DVM, Dr. med. vet., DipECVDI  
European Specialist in Veterinary Diagnostic Imaging, Cert. Radiology,  
Senior lecturer University of Giessen, Germany, Veterinary Faculty, Department of Radiology  
Nele.Eley@sonopath.com

**BREED**

Doberman Pinscher

**SEX**

MN

**AGE**

6 Years, 3 Months

**INTERPRETED BY**

Nele Eley, DVM  
Dr. med. Vet. DipECVDI

**HOSPITAL NAME**

South Bay Animal  
Hospital

**REFERRING VET**

Ravinder Atwal, DVM,  
CCRP

**INVOICE**

47449

**DATE**

9-16-21