

**PATIENT**

Daisy Toffoletto

PRESENTING CLINICAL SIGNS

Several day history of lethargy and anorexia. Bloodwork unremarkable. Intermittent elevated respiratory rate and effort noted at home by owner and in hospital.

SPECIES

Canine

RADIOGRAPHIC STUDY OF THE THORAX

Right/left lateral and ventrodorsal views totaling 4 images available for review.

BREED

Golden Retriever

RADIOGRAPHIC FINDINGS

The surrounding bony structures are within normal limits.

The extrathoracic soft tissues present homogeneous without abnormalities.

SEX

Female Spayed

The heart is of normal size and shape and there is no evidence of cardiac chamber or vascular enlargement. The vertebral heart score is 10 which is within the reference range. The pulmonary vasculature is within normal limits.

AGE

1 Year

The cranial mediastinum presents the expected soft tissue opacity. The mediastinal width is less than twice the width of the vertebral column at the same level.

Moderate redundancy of the dorsal tracheal ligament appears to be present in the caudal cervical trachea. Course and width of the rest of the trachea present within normal limits.

INTERPRETED BY

Nele Eley, DVM
Dr. med. Vet. DipECVDI

The bronchial tree presents with thin walls and tapers uniformly towards the periphery as expected.

The lung parenchyma presents the expected architecture and opacity. The intrapulmonary vascular branching is seen up to the third order lung vessels.

HOSPITAL NAME

Animal Health
Partners

The diaphragm is well delineated with even surface and the expected mild cranial bulging of the diaphragmatic cupola.

RADIOGRAPHIC DIAGNOSIS

- Radiographically normal thorax.

REFERRING VET

Dr. Shannon
Westgarth

INTERPRETATION OF THE FINDINGS & FURTHER RECOMMENDATIONS

The radiographic study reveals no evidence of structural pathology in the lung, bronchial tree, or cardiovascular system. Full internal medicine workup may be required. Metabolic causes, systemic disease, and cardiovascular pathology including valvular insufficiencies and arrhythmia should be ruled out depending on the clinical correlation.

INVOICE

47363

DATE

9-15-21



PATIENT

Daisy Toffoletto

SPECIES

Canine

BREED

Golden Retriever

SEX

Female Spayed

AGE

1 Year

INTERPRETED BY

Nele Eley, DVM
Dr. med. Vet. DipECVDI

HOSPITAL NAME

Animal Health
Partners

REFERRING VET

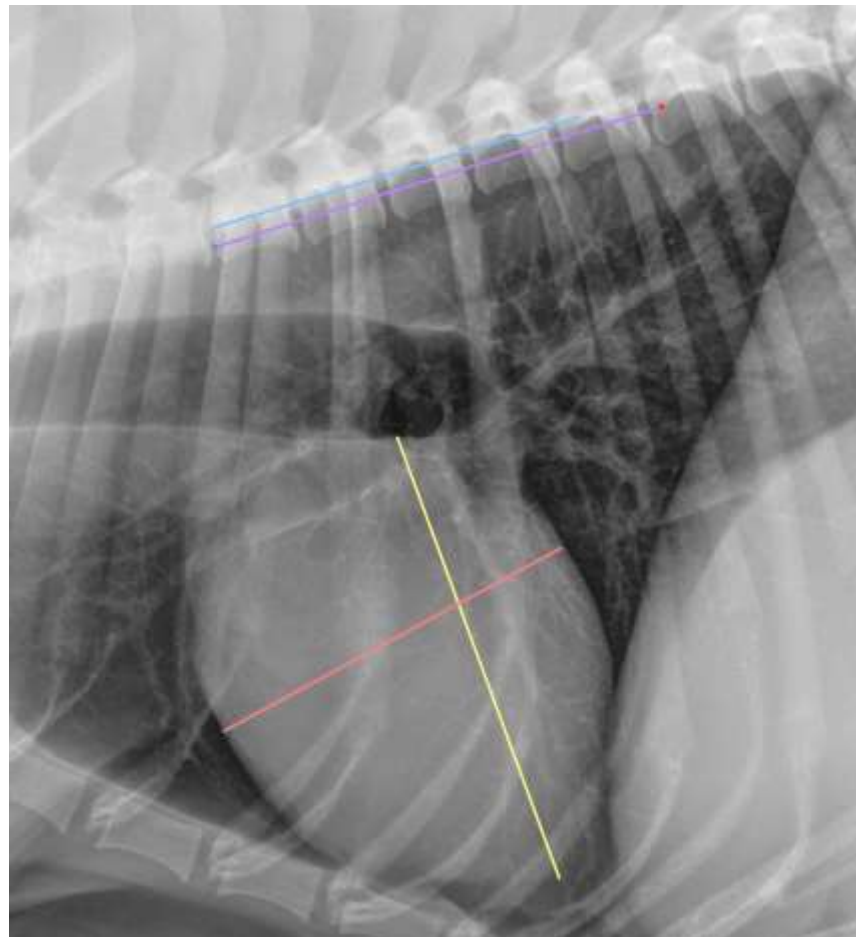
Dr. Shannon
Westgarth

INVOICE

47363

DATE

9-15-21



The information and recommendations provided are based on the images presented by the referring veterinarian. No evaluation can be communicated regarding pathology that was not visible in the image/video clips provided.

Thank you for this referral. If the clinical or image interpretation does not parallel your findings or if I can be of any further assistance please contact me.

Nele Eley, DVM, Dr. med. vet., DipECVDI
European Specialist in Veterinary Diagnostic Imaging, Cert. Radiology,
Senior lecturer University of Giessen, Germany, Veterinary Faculty, Department of Radiology
Nele.Eley@sonopath.com