

**PATIENT**

Gus Kelly

PRESENTING CLINICAL SIGNS

Unilateral left sided epistaxis 1 week. Reverse sneezing started 2 weeks earlier.

SPECIES

Canine

COMPUTED TOMOGRAPHIC STUDY OF THE NASAL CAVITY

Plain and post contrast studies available for review.

BREEDGerman Shepherd
Mix**COMPUTED TOMOGRAPHIC FINDINGS**

Extensive turbinate destruction is noted within the left nasal cavity. Part of the middle nasal concha and ethmoid turbinates are still maintained. The left nasal cavity is filled with hypoattenuating contrast negative material. Interruption of the nasal septum with rightward deviation is noted in the mid third of the left nasal cavity. The left frontal sinus and nasal choana contain hypoattenuating contrast negative material. No evidence of aggressive osteolytic changes is seen and there is no evidence of hyperostosis or foreign material.

SEX

MN

COMPUTED TOMOGRAPHIC DIAGNOSIS

- Severe erosive rhinitis and hypoattenuating material within the left nasal cavity, left frontal sinus, maxillary recess, and nasal choana.

AGE

8 Years

INTERPRETATION OF THE FINDINGS & FURTHER RECOMMENDATIONS

The CT findings are suggestive for severe left sided erosive rhinosinusitis with excessive hemorrhage. The hypoattenuating material within the nasal cavity is contrast negative and may represent fluid as well as blood clots. Unilateral fungal rhinitis, such as with aspergillus species, is considered a primary differential diagnosis. Soft tissue neoplasia with aggressive biological behavior such as round cell neoplasia is a potential but less likely differential diagnosis. Further definition by means of rhinoscopy with sampling for culture and histology is recommended if not performed already.

INTERPRETED BYNele Eley, DVM
Dr. med. Vet. DipECVDI**HOSPITAL NAME**Scottsdale Veterinary
Clinic**REFERRING VET**

Dr. Hertz

INVOICE

54088

DATE

9-14-22



PATIENT

Gus Kelly

SPECIES

Canine

BREED

German Shepherd
Mix

SEX

MN

AGE

8 Years

INTERPRETED BY

Nele Eley, DVM
Dr. med. Vet. DipECVDI

HOSPITAL NAME

Scottsdale Veterinary
Clinic

REFERRING VET

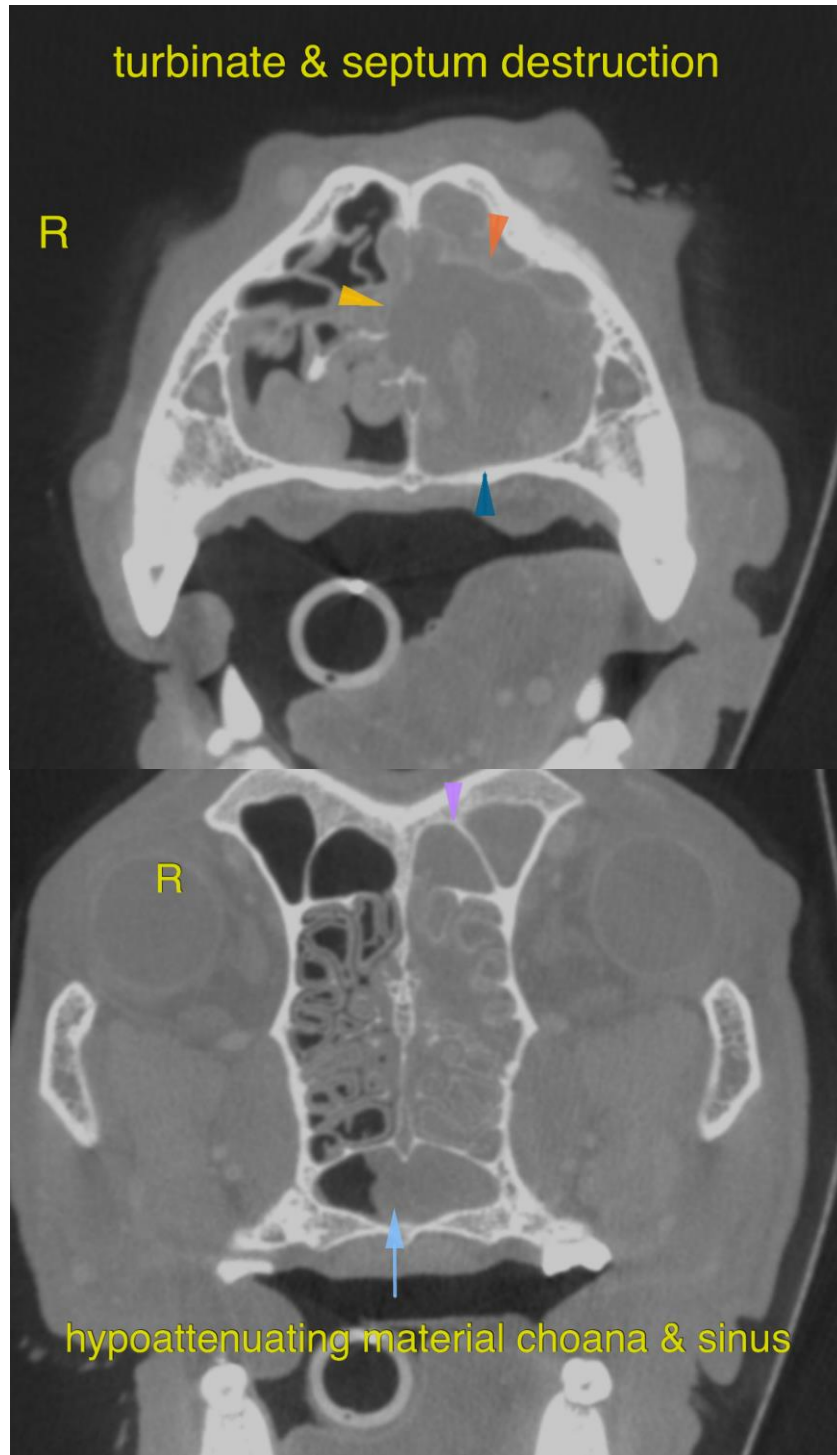
Dr. Hertz

INVOICE

54088

DATE

9-14-22





PATIENT

Gus Kelly

The information and recommendations provided are based on the images presented by the referring veterinarian/sonographer. No evaluation can be communicated regarding pathology that was not visible in the image/video clips provided.

Thank you for this referral. If the clinical or image interpretation does not parallel your findings or if I can be of any further assistance please contact me.

SPECIES

Canine

Nele Eley, DVM, Dr. med. vet., DipECVDI
European Specialist in Veterinary Diagnostic Imaging, Cert. Radiology,
Senior lecturer University of Giessen, Germany, Veterinary Faculty, Department of Radiology
Nele.Eley@sonopath.com

BREED

German Shepherd
Mix

SEX

MN

AGE

8 Years

INTERPRETED BY

Nele Eley, DVM
Dr. med. Vet. DipECVDI

HOSPITAL NAME

Scottsdale Veterinary
Clinic

REFERRING VET

Dr. Hertz

INVOICE

54088

DATE

9-14-22