

**PATIENT**

Rodino Mia

**PRESENTING CLINICAL SIGNS**

Obtained from a breeder 1 week ago. Has been sneezing and had a gagging dry cough since picking her up. Occurs several times each day/night. Sleeping a lot.  
Abnormal PE/Chem/CBC/UA Results: Temperature 102.0. Heart and lungs auscultate normal. No cough on tracheal palpation. In-house WBC count 17.750. Fecal testing is negative today with several previous doses of pyrantel.

**SPECIES**

Canine

**RADIOGRAPHIC STUDY OF THE THORAX****BREED**

Maltese

Right/left lateral and dorsoventral views totaling 3 images available for review.

**RADIOGRAPHIC FINDINGS**

The surrounding bony structures are within normal limits.

**SEX**

Female

The extrathoracic soft tissues present homogeneous without abnormalities.

The heart is of normal size and shape and there is no evidence of cardiac chamber or vascular enlargement. The pulmonary vasculature is within normal limits.

**AGE**

11 Weeks

The cranial mediastinum presents the expected soft tissue opacity. The mediastinal width is less than twice the width of the vertebral column at the same level.

**INTERPRETED BY**Nele Eley, DVM  
Dr. med. Vet. DipECVDI

The trachea is normal in diameter and presents the anticipated course. The luminal outline of the trachea is smooth.

Mild generalized bronchial wall enhancement with mild peribronchial cuffing and a diffuse increase in interstitial background opacity of the lung are seen.

**HOSPITAL NAME**Gentle Doctor Animal  
Hospital

The diaphragm is well delineated with even surface and the expected mild cranial bulging of the diaphragmatic cupola.

**RADIOGRAPHIC DIAGNOSIS**

- Moderate active bronchointerstitial lung pattern.

**REFERRING VET**

Dr. Adrienne Kanne

**INTERPRETATION OF THE FINDINGS & FURTHER RECOMMENDATIONS**

The radiographic findings are suggestive for bronchopneumopathy / bronchopneumonia. Consider infectious bronchitis/bronchopneumonia such as viral, bacterial, parasitic, or less likely protozoal a high potential in this patient. Allergic bronchitis cannot be ruled out. Consider further definition by means of lower airway sampling should the initiated test results be inconclusive.

**INVOICE**

47398

**DATE**

9-14-21



**PATIENT**

Rodino Mia

**SPECIES**

Canine

**BREED**

Maltese

**SEX**

Female

**AGE**

11 Weeks

**INTERPRETED BY**

Nele Eley, DVM  
Dr. med. Vet. DipECVDI

**HOSPITAL NAME**

Gentle Doctor Animal  
Hospital

**REFERRING VET**

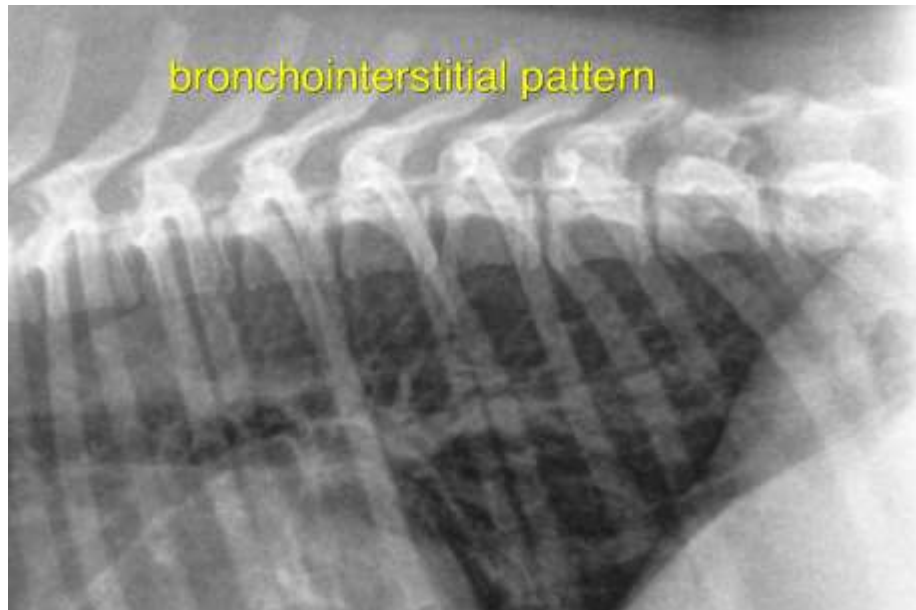
Dr. Adrienne Kanne

**INVOICE**

47398

**DATE**

9-14-21



The information and recommendations provided are based on the images presented by the referring veterinarian. No evaluation can be communicated regarding pathology that was not visible in the image/video clips provided.

Thank you for this referral. If the clinical or image interpretation does not parallel your findings or if I can be of any further assistance please contact me.

**Nele Eley**, DVM, Dr. med. vet., DipECVDI  
European Specialist in Veterinary Diagnostic Imaging, Cert. Radiology,  
Senior lecturer University of Giessen, Germany, Veterinary Faculty, Department of Radiology  
Nele.Eley@sonopath.com