



PATIENT PRESENTING CLINICAL SIGNS

Patient: Puchi Dole
Species: Canine
Breed: Mixed Medium Breed
Sex: F
Age: 4 Years

2 week history of lethargy, anorexia and weight loss, diarrhea. Presented on 9/9/21 CBC - high WBC 34,980 SMA - high ALKP, high TBil, high Globulins Lytest - na/k -26 Fecal - negative Thoracic Radiographs - clear lungs Abominal Radiographs - Abdominal effusion. Started on IV LRS vitamin B -12 Ceftriaxone 2.5 ml iv bid Metronidazole 250 mg po bid Mirtazapin 15 mg - 1/2 tablet po sid Dexamethasone 2 ml iv sid Famotidine 1 ml iv sid Abdominal Ultrasound - see results. Right liver changes compatible with possible neoplasia (adenoma vs carcinoma), Hepatitis, cholangiohepatitis. Enteritis, peritonela effusion. Possible pancreatitis vs pancreatic neoplasia and small intestinal mass. Referral for CT SCAN to rule out Neoplasia - Right liver, pancreas and right upper quadrant area.

Abnormal PE/Chem/CBC/UA Results: CBC - 9/13/21 - Hight WBC (38,580), Anemia - hgb 9.2, hct -23.8 CHEM - ALKP, GGT, TBIL and LIPA increased

COMPUTED TOMOGRAPHIC STUDY OF THE ABDOMEN

Plain and post contrast studies available for review.

COMPUTED TOMOGRAPHIC FINDINGS

There is a large multiloculated ill-defined mass in the right cranial abdomen with a mineralizing component in the position of the right limb and body of the pancreas measuring approximately 3.0 cm in diameter. This part of the mass appears to blend into the duodenal wall with transmural loss of wall layering and appears to connect with the duodenal lumen as well. The large multiloculated portion of the mass measures approximately 10.0 cm in diameter and blends into the aforementioned mineralizing mass in the pancreatic position as well as into the portal lymph nodes and hepatic parenchyma. The portal vein is encompassed and compressed by this mass.

Multifocal moderate to severe mesenteric lymphadenomegaly is seen. There is a moderate amount of peritoneal fluid.

The spleen presents volume contracted.

No abnormalities of the kidneys is seen.

The urinary bladder is severely distended. No structural pathology is seen within the urinary bladder.

The adrenal glands present within normal limits.

COMPUTED TOMOGRAPHIC DIAGNOSIS

- Large ill-defined multiloculated mass in the right cranial abdomen with hepatic, lymph node, pancreatic, and duodenal involvement.
- Portal vein compression
- Portal hypertension
- Ascites
- Multiple abdominal lymphadenomegaly.

INVOICE

47396

DATE

9-14-21

INTERPRETED BY

Nele Eley, DVM
 Dr. med. Vet. DipECVDI

HOSPITAL NAME

Veterinary Image
 Center

REFERRING VET

Dr. L. Ricci, DVM



PATIENT

Puchi Dole

SPECIES

Canine

BREED

Mixed Medium Breed

SEX

F

AGE

4 Years

INTERPRETED BY

Nele Eley, DVM
Dr. med. Vet. DipECVDI

HOSPITAL NAME

Veterinary Image
Center

REFERRING VET

Dr. L. Ricci, DVM

INVOICE

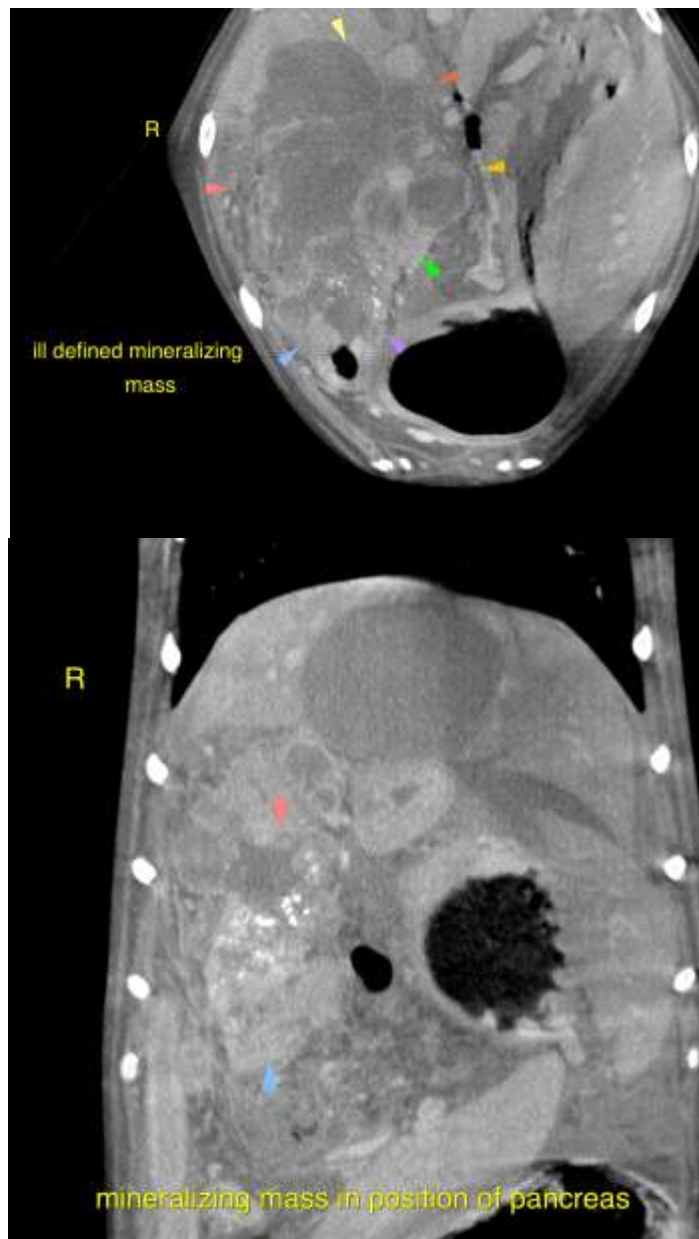
47396

DATE

9-14-21

INTERPRETATION OF THE FINDINGS & FURTHER RECOMMENDATIONS

The CT findings are highly suggestive of abdominal neoplasia with involvement of the pancreas, lymph nodes, duodenum, and liver. Pancreatic carcinoma with regional metastatic disease and carcinomatosis would be one potential differential diagnosis; however, hepatic or lymph node origin cannot be ruled out as well. Opportunistic infection such as with mycobacterial or fungi cannot be ruled out entirely as a differential diagnosis but is considered by far less likely based on the CT findings. Final diagnosis would require sampling for histology. The mass is not in a resectable position as per the direct involvement and compression of the portal vein.





PATIENT

Puchi Dole

The information and recommendations provided are based on the images presented by the referring veterinarian. No evaluation can be communicated regarding pathology that was not visible in the image/video clips provided.

Thank you for this referral. If the clinical or image interpretation does not parallel your findings or if I can be of any further assistance please contact me.

SPECIES

Canine

Nele Eley, DVM, Dr. med. vet., DipECVDI
European Specialist in Veterinary Diagnostic Imaging, Cert. Radiology,
Senior lecturer University of Giessen, Germany, Veterinary Faculty, Department of Radiology
Nele.Eley@sonopath.com

BREED

Mixed Medium Breed

SEX

F

AGE

4 Years

INTERPRETED BY

Nele Eley, DVM
Dr. med. Vet. DipECVDI

HOSPITAL NAME

Veterinary Image
Center

REFERRING VET

Dr. L. Ricci, DVM

INVOICE

47396

DATE

9-14-21