



**PATIENT**

Cash Timm

**PRESENTING CLINICAL SIGNS**

P has been coughing/wheezing since July. Treated for kennel cough with Amoxicillin and Hydrocodone. O noted no significant improvement. Rhinoscopy had no significant findings. Radiographs showed some changes.

**SPECIES**

Canine

**COMPUTED TOMOGRAPHIC STUDY OF THE THORAX**

Plain study available for review.

**BREED**

French Brittany  
Spaniel

**COMPUTED TOMOGRAPHIC FINDINGS**

The lungs are not fully included owing to the limitations of the field of view. The visible lung presents multifocal peripheral and peribronchial interstitial infiltrates. Occasional subpleural and interstitial bands are seen. There is mild generalized bronchial wall enhancement.

**SEX**

Male Neutered

**COMPUTED TOMOGRAPHIC DIAGNOSIS**

- Mild to moderate multifocal bronchointerstitial lung pattern without concurrent mediastinal lymphadenomegaly.

**AGE**

3 Years, 3 Months

**INTERPRETATION OF THE FINDINGS & FURTHER RECOMMENDATIONS**

The CT findings are compatible with active lower airway disease. Consider infectious bronchitis such as viral, bacterial, parasitic, or protozoal including canine infectious tracheobronchitis versus eosinophilic / allergic bronchopneumopathy. Lower airway endoscopy with airway sampling would be ideal for further definition.

**INTERPRETED BY**

Nele Eley, DVM  
Dr. med. Vet. DipECVDI

**HOSPITAL NAME**

State Avenue Vet  
Clinic

**REFERRING VET**

Dr. Raul Casas-Dolz

**INVOICE**

47395

**DATE**

9-14-21



**PATIENT**

Cash Timm

**SPECIES**

Canine

**BREED**

French Brittany  
Spaniel

**SEX**

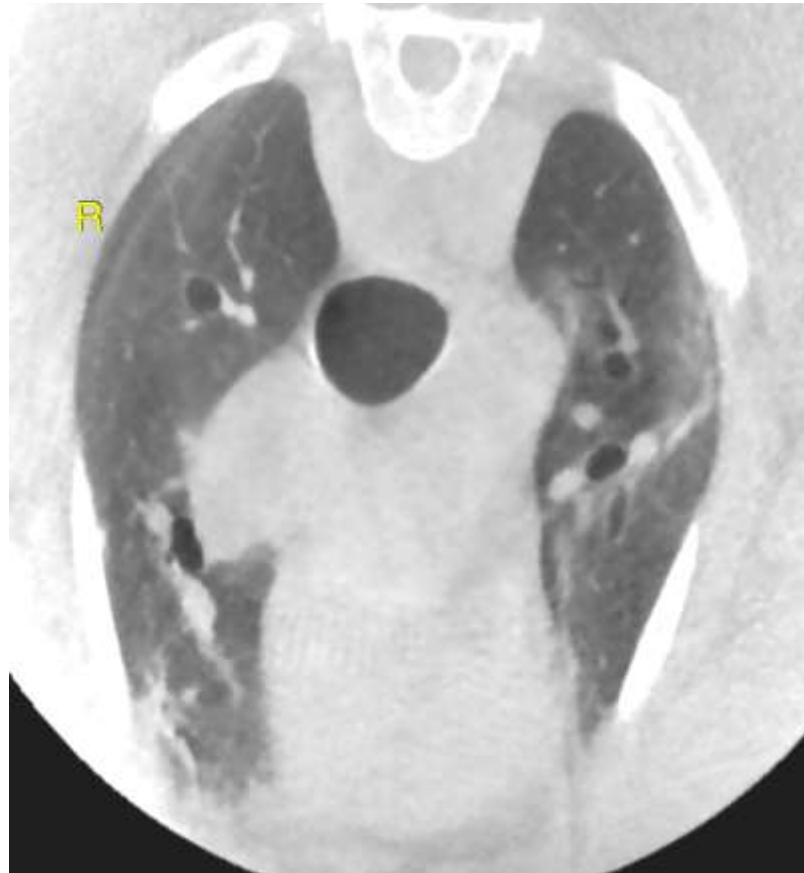
Male Neutered

**AGE**

3 Years, 3 Months

**INTERPRETED BY**

Nele Eley, DVM  
Dr. med. Vet. DipECVDI



**HOSPITAL NAME**

State Avenue Vet  
Clinic

**REFERRING VET**

Dr. Raul Casas-Dolz

**INVOICE**

47395

**DATE**

9-14-21

The information and recommendations provided are based on the images presented by the referring veterinarian. No evaluation can be communicated regarding pathology that was not visible in the image/video clips provided.

Thank you for this referral. If the clinical or image interpretation does not parallel your findings or if I can be of any further assistance please contact me.

**Nele Eley**, DVM, Dr. med. vet., DipECVDI  
European Specialist in Veterinary Diagnostic Imaging, Cert. Radiology,  
Senior lecturer University of Giessen, Germany, Veterinary Faculty, Department of Radiology  
Nele.Eley@sonopath.com