

**PATIENT**

Tyrone Hamilton

PRESENTING CLINICAL SIGNS

persistent rhinitis.

SPECIES

Feline

COMPUTED TOMOGRAPHIC STUDY OF THE HEAD

Plain and post contrast studies available for review.

BREED

Devon Rex

COMPUTED TOMOGRAPHIC FINDINGS

Moderate asymmetric turbinate destruction is seen in both nasal cavities. There is fluid accumulation and mucosal swelling within both nasal cavities. The right frontal sinus is filled with fluid attenuating material. Mild swelling of the peripheral mucosal lining is noted as well as mild hyperostosis. The right presphenoidal sinus contains a mild amount of fluid as well.

SEX

MN

Both temporomandibular joints present congruent joint spaces with even subchondral bone surfaces and are considered within normal limits.

AGE

3 Years

The right tympanic bulla presents osseous thickening and obliteration with fluid attenuating material. No evidence of intracranial extension is seen. The right external auditory meatus contains a mild amount of hypoattenuating material within its medial aspect.

The brain presents no deviation from normal anatomy and symmetry. The brain parenchyma is homogeneous and within normal limits for attenuation and distribution of contrast enhancement. The ventricular system is non-dilated and symmetric.

INTERPRETED BY

Nele Eley, DVM
Dr. med. Vet. DipECVDI

Minimal symmetric enlargement of the right medial retropharyngeal lymph node is seen.

COMPUTED TOMOGRAPHIC DIAGNOSIS

- Moderate bilateral mildly destructive rhinosinusitis.
- Chronic right sided otitis media.
- Mild right sided otitis externa.
- Minimal lymphadenomegaly of the right medial retropharyngeal lymph node.

HOSPITAL NAME

Suncoast Veterinary

INTERPRETATION OF THE FINDINGS & FURTHER RECOMMENDATIONS**REFERRING VET**

Byron Young

The CT study reveals mildly destructive chronic rhinosinusitis. Consider viral/lymphoplasmacytic and bacterial rhinitis a potential. There is no evidence of a mass. No typical changes of fungal rhinitis or foreign body related pathology.

INVOICE

47394

The concurrent presence of right sided otitis media with evidence of chronicity should be noted. Ooscopic workup should be considered along with rhinoscopy and sampling for culture.

The lymph node changes are compatible with reactive hyperplasia.

DATE

9-13-21



PATIENT

Tyrone Hamilton

SPECIES

Feline

BREED

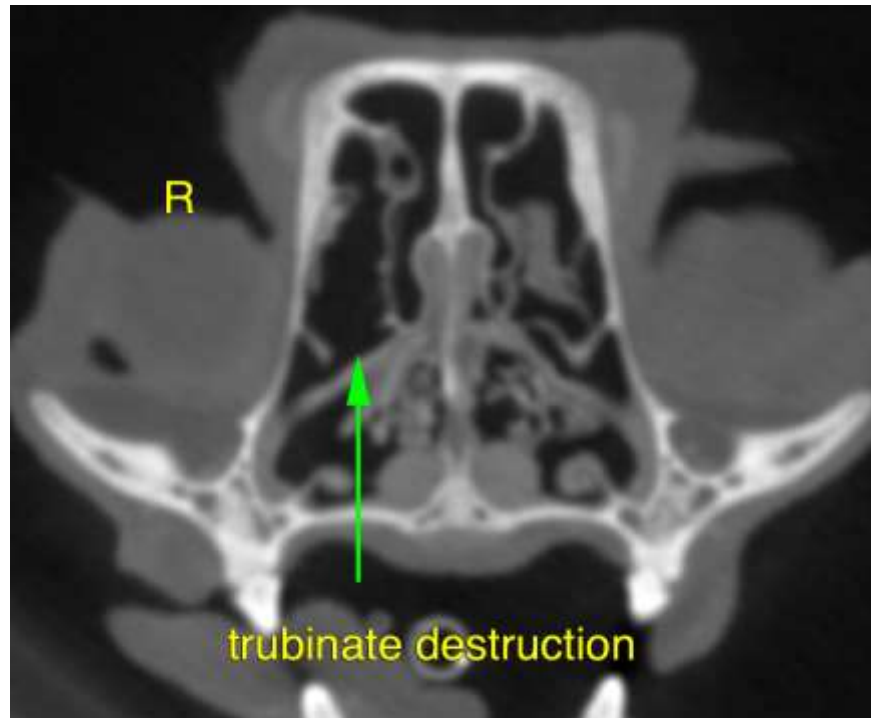
Devon Rex

SEX

MN

AGE

3 Years



INTERPRETED BY

Nele Eley, DVM
Dr. med. Vet. DipECVDI

The information and recommendations provided are based on the images presented by the referring veterinarian. No evaluation can be communicated regarding pathology that was not visible in the image/video clips provided.

HOSPITAL NAME

Suncoast Veterinary

Thank you for this referral. If the clinical or image interpretation does not parallel your findings or if I can be of any further assistance please contact me.

REFERRING VET

Byron Young

Nele Eley, DVM, Dr. med. vet., DipECVDI
European Specialist in Veterinary Diagnostic Imaging, Cert. Radiology,
Senior lecturer University of Giessen, Germany, Veterinary Faculty, Department of Radiology
Nele.Eley@sonopath.com

INVOICE

47394

DATE

9-13-21