

**PATIENT**

Tsavo Grau

PRESENTING CLINICAL SIGNS

Firm mass on dorsal muzzle, present for years. Recently has had rapid growth
Abnormal PE/Chem/CBC/UA Results: 6 cm firm mass dorsal muzzle to L of midline.

SPECIES

Canine

COMPUTED TOMOGRAPHIC STUDY OF THE HEAD

Plain and post contrast studies available for review.

BREED

Rhodesian Tidgeback

COMPUTED TOMOGRAPHIC FINDINGS

A large soft tissue attenuating ovoid ill-defined mass is seen lateral of the left maxilla and nasal bone. The mass measures approximately 7.0 cm in length and 4.0 cm in width and extends from the Triadan 202 through the Triadan 207. Triadan 208 is absent. Extensive aggressive osteolytic changes of the left maxillary, palatal, and nasal bones are seen allowing for invasion of the left nasal cavity with regional turbinate destruction. The mass presents moderate nonuniform enhancement on the post contrast study.

SEX

MN

Lytic changes of the tooth roots and crowns of the Triadans 202, 203, 204, 205, and 206 are seen.

AGE

12 Years

The left submandibular lymph nodes present mild symmetric enlargement. The medial retropharyngeal lymph nodes present within normal limits.

COMPUTED TOMOGRAPHIC DIAGNOSIS**INTERPRETED BY**

Nele Eley, DVM
Dr. med. Vet. DipECVDI

- Large soft tissue mass meeting neoplastic criteria with secondary polyostotic aggressive osteolysis in the left maxilla.
- Mild left submandibular lymphadenomegaly.

INTERPRETATION OF THE FINDINGS & FURTHER RECOMMENDATIONS**HOSPITAL NAME**

Healing Spirit Animal
Wellness

The CT findings are compatible with malignant soft tissue neoplasia or odontogenic neoplasia with secondary bone lysis. Consider fibrosarcoma, other soft tissue sarcoma, and less likely odontogenic neoplasia a potential. Final diagnosis will require sampling for histology.

The lymph node changes are suggestive for reactive hyperplasia. Early metastatic spread cannot be ruled out and fine needle aspiration of the left submandibular lymph nodes is recommended.

REFERRING VET

Desen Ertunc

INVOICE

47393

DATE

9-13-21



PATIENT

Tsavo Grau

SPECIES

Canine

BREED

Rhodesian Tidgeback

SEX

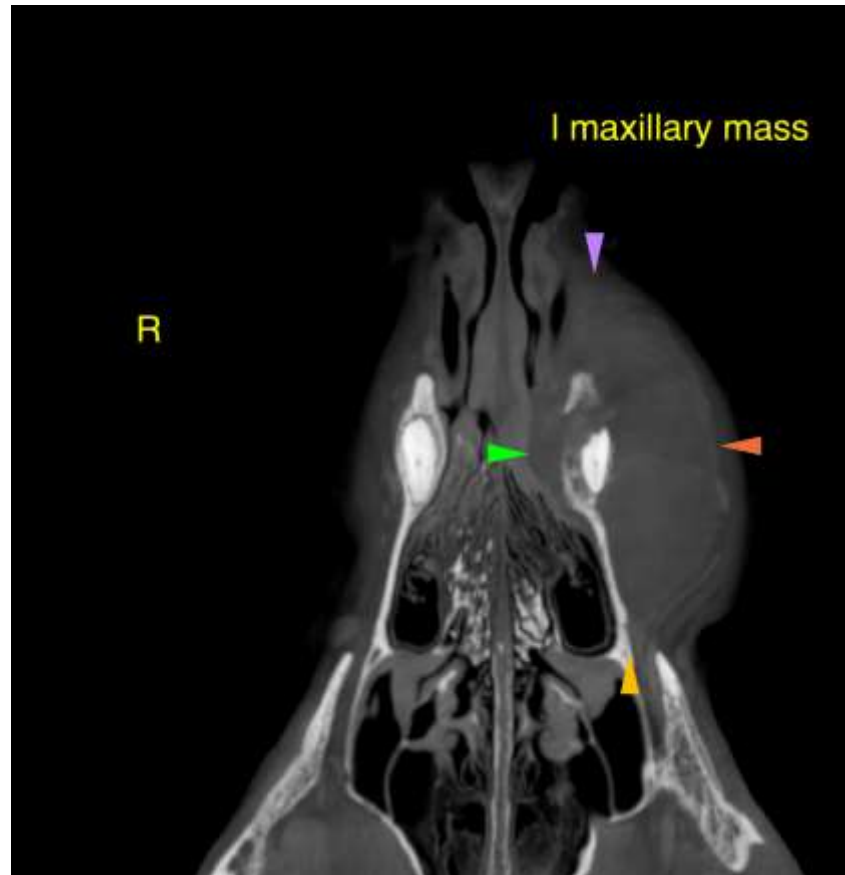
MN

AGE

12 Years

INTERPRETED BY

Nele Eley, DVM
Dr. med. Vet. DipECVDI



HOSPITAL NAME

Healing Spirit Animal
Wellness

REFERRING VET

Desen Ertunc

INVOICE

47393

DATE

9-13-21

The information and recommendations provided are based on the images presented by the referring veterinarian. No evaluation can be communicated regarding pathology that was not visible in the image/video clips provided.

Thank you for this referral. If the clinical or image interpretation does not parallel your findings or if I can be of any further assistance please contact me.

Nele Eley, DVM, Dr. med. vet., DipECVDI
European Specialist in Veterinary Diagnostic Imaging, Cert. Radiology,
Senior lecturer University of Giessen, Germany, Veterinary Faculty, Department of Radiology
Nele.Eley@sonopath.com