



PATIENT

Skye Guillen

PRESENTING CLINICAL SIGNS

Pregnancy check. Mated 47 days ago.
Abnormal PE/Chem/CBC/UA Results: Pet is BAR. Clear OU and AS. AD: mild to moderate erythema, dark brown exudate and mild swelling. Panting, no obvious heart murmur. Distended abdomen, normal sized mammary gland. Skin: large, sl erythematous moist dermatitis on R side of face.

SPECIES

Canine

RADIOGRAPHIC STUDY OF THE ABDOMEN

Lateral and ventrodorsal views of the abdomen totaling 2 images available for review.

BREED

Golden Retriever

RADIOGRAPHIC FINDINGS

The abdominal serosal detail is good.

SEX

F

The gastrointestinal tract is postprandial.

No uterine enlargement with gestational chambers and no mineralized fetal structures can be seen.

AGE

4 Years

The liver, spleen, and kidneys present within expected limits.

RADIOGRAPHIC DIAGNOSIS

- No radiographic evidence of gestational chambers or mineralized fetuses.

INTERPRETED BY

Nele Eley, DVM
Dr. med. Vet. DipECVDI

INTERPRETATION OF THE FINDINGS & FURTHER RECOMMENDATIONS

The radiographic study does not confirm intact pregnancy beyond the limits of more than 45 days post-LH surge. No fetal structures can be identified.

HOSPITAL NAME

DPC Veterinary
Hospital

REFERRING VET

Dr. Rivera

INVOICE

54065

DATE

9-12-22



PATIENT

Skye Guillen

SPECIES

Canine

BREED

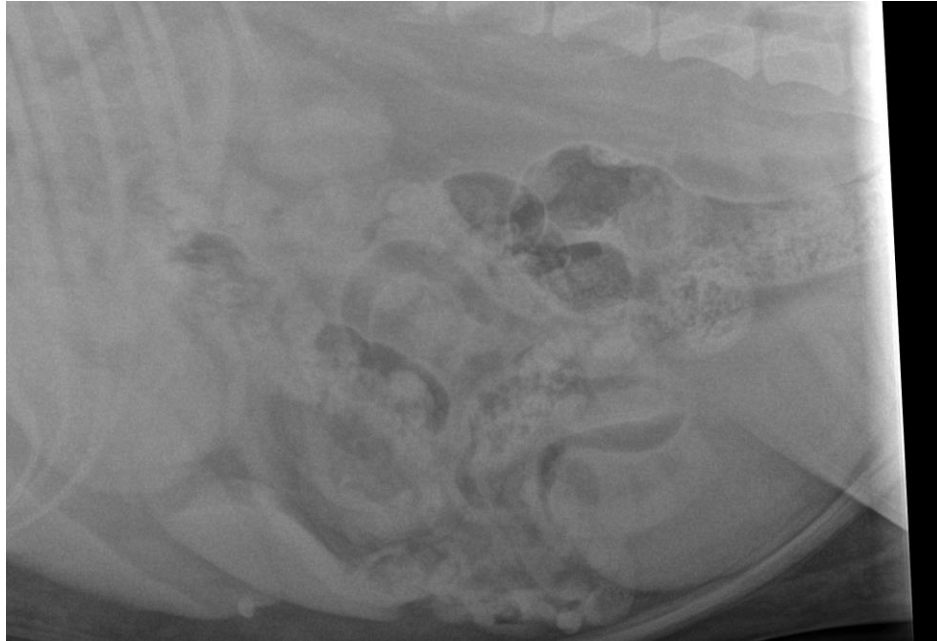
Golden Retriever

SEX

F

AGE

4 Years



INTERPRETED BY

Nele Eley, DVM
Dr. med. Vet. DipECVDI

HOSPITAL NAME

DPC Veterinary
Hospital

REFERRING VET

Dr. Rivera

INVOICE

54065

DATE

9-12-22

The information and recommendations provided are based on the images presented by the referring veterinarian/sonographer. No evaluation can be communicated regarding pathology that was not visible in the image/video clips provided.

Thank you for this referral. If the clinical or image interpretation does not parallel your findings or if I can be of any further assistance please contact me.

Nele Eley, DVM, Dr. med. vet., DipECVDI
European Specialist in Veterinary Diagnostic Imaging, Cert. Radiology,
Senior lecturer University of Giessen, Germany, Veterinary Faculty, Department of Radiology
Nele.Eley@sonopath.com