

**PATIENT**

Axel Chopp

PRESENTING CLINICAL SIGNS

4 week history of right knee pain , laxity dated by rehab vet. Exam: right knee extension pain, mild laxity; Left knee normal
Abnormal PE/Chem/CBC/UA Results: NA

SPECIES

Canine

ULTRASONOGRAPHIC FINDINGS**Right & Left Stifle****BREED**German Short Haired
Pointer

At this time, no evidence of cruciate ligament injury is seen in the right and left stifle. The cranial and caudal cruciate ligaments present smoothly delineated with uniform internal echoarchitecture and continuous. No evidence of periligamentous effusion or generalized joint effusion is seen. The synovial membranes are smooth and thin. The infrapatellar fat pad presents uniform echotexture. No periarticular osteophytes are seen. The patella tendon is smoothly delineated and intact in both stifles.

SEX

Male Neutered

ULTRASONOGRAPHIC DIAGNOSIS

- Normal ultrasonographic findings of both stifle joints with no evidence of cruciate ligament injury.

AGE

1.5 Years

INTERPRETATION OF THE FINDINGS & FURTHER RECOMMENDATIONS

The cranial cruciate ligament of the right and left stifle joint presents intact and within the expected ultrasonographic limits. There is no evidence of cruciate ligament injury found ultrasonographically. Correlate with the clinical findings and consider clinical as well as ultrasonographic recheck as indicated.

INTERPRETED BYNele Eley, DVM
Dr. med. Vet. DipECVDI**HOSPITAL NAME**Colorado Animal
Specialty &
Emergency**REFERRING VET**

Gaynor

INVOICE

54074

DATE

9-12-22



PATIENT

Axel Chopp

SPECIES

Canine

BREED

German Short Haired
Pointer

SEX

Male Neutered

AGE

1.5 Years

INTERPRETED BY

Nele Eley, DVM
Dr. med. Vet. DipECVDI

HOSPITAL NAME

Colorado Animal
Specialty &
Emergency

REFERRING VET

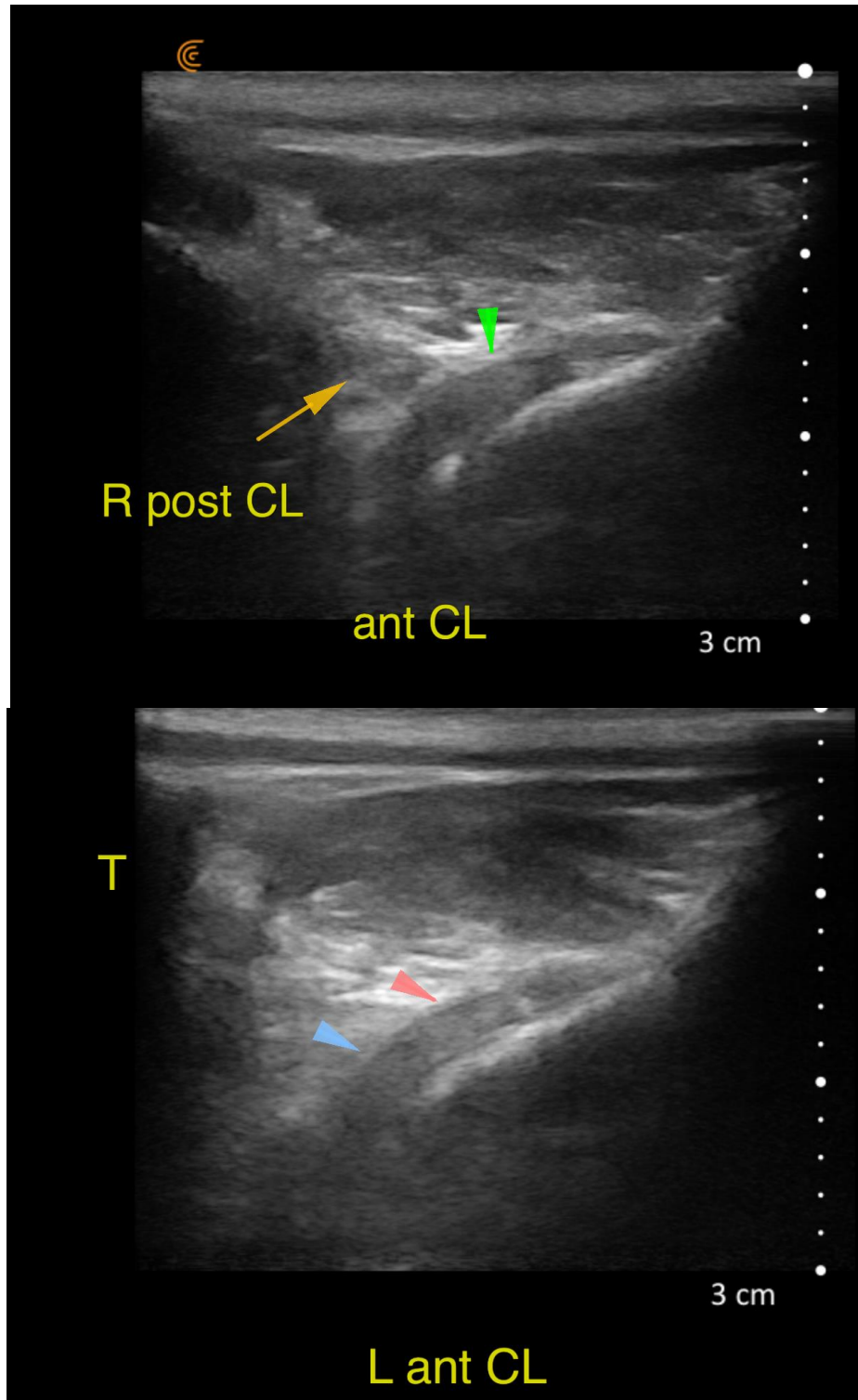
Gaynor

INVOICE

54074

DATE

9-12-22





PATIENT

Axel Chopp

The information and recommendations provided are based on the images presented by the referring veterinarian/sonographer. No evaluation can be communicated regarding pathology that was not visible in the image/video clips provided.

Thank you for this referral. If the clinical or image interpretation does not parallel your findings or if I can be of any further assistance please contact me.

SPECIES

Canine

Nele Eley, DVM, Dr. med. vet., DipECVDI
European Specialist in Veterinary Diagnostic Imaging, Cert. Radiology,
Senior lecturer University of Giessen, Germany, Veterinary Faculty, Department of Radiology
Nele.Eley@sonopath.com

BREED

German Short Haired
Pointer

SEX

Male Neutered

AGE

1.5 Years

INTERPRETED BY

Nele Eley, DVM
Dr. med. Vet. DipECVDI

HOSPITAL NAME

Colorado Animal
Specialty &
Emergency

REFERRING VET

Gaynor

INVOICE

54074

DATE

9-12-22